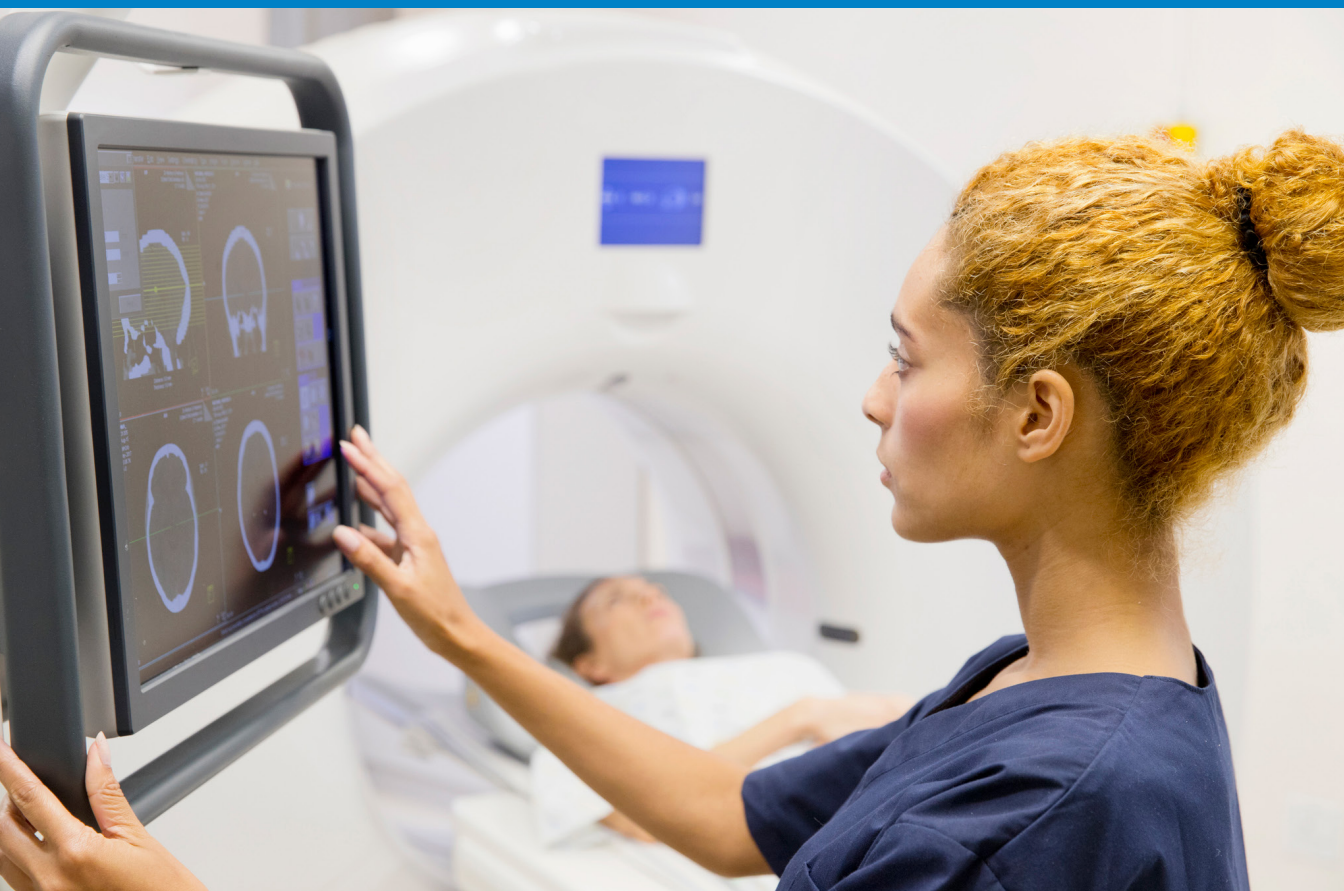

ACS TQIP BEST PRACTICES GUIDELINES IN IMAGING



AMERICAN COLLEGE OF SURGEONS
*Inspiring Quality:
Highest Standards, Better Outcomes*

100+years



THE
COMMITTEE
ON **TRAUMA**

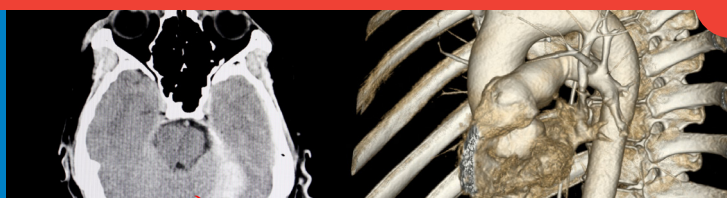ACR[®]
AMERICAN COLLEGE OF
RADIOLOGY
QUALITY IS OUR IMAGE



THE AMERICAN SOCIETY OF
EMERGENCY RADIOLOGY

Table of Contents

Introduction.....	3
1. Overview.....	4
Part 1: General Issues	4
Part 2: Contrast Considerations	8
Part 3: Sedation	10
2. Brain Imaging.....	15
3. Cervical Spine Imaging.....	21
4. Imaging for Blunt Cerebrovascular Injury	32
5. Chest Imaging	36
6. Abdominal Imaging.....	40
7. Genitourinary Imaging	45
8. Thoracic and Lumbar Spine Imaging.....	48
9. Whole-Body CT Imaging.....	51
10. Imaging in Orthopaedic Trauma	56
11. Imaging for Extremity Vascular Injury.....	60
12. Interventional Radiology for Traumatic Injuries	64
13. Imaging in Penetrating Neck Injury.....	72
14. Imaging in Penetrating Transthoracic Trauma	76
15. Imaging in Penetrating Abdominal Trauma	80
16. Imaging in the Trauma Patient Who Is Morbidly Obese.....	84
17. Imaging in the Trauma Patient Who Is Pregnant	88
18. Imaging in Geriatric Patients with Low Energy Mechanism Injuries	92
19. Imaging for Intentional Injury in Children.....	96
20. Imaging at Rural Trauma Centers	101
21. Dealing with Incidental Findings	105
22. Performance Improvement and Implementation	109
Acronyms	111
Appendix	112
Expert Panel.....	113



INTRODUCTION

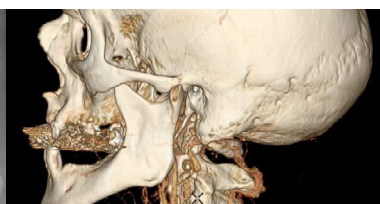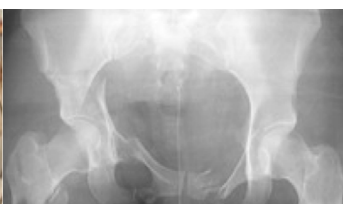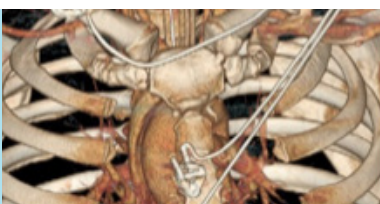
Radiologic imaging remains a critical tool of emergency and trauma providers for the initial assessment of patients presenting with injury. With the introduction of the Advanced Trauma Life Support® (ATLS®) course by the American College of Surgeons (ACS) Committee on Trauma (COT) in the early 1980s, chest and pelvic radiographs became a primary adjunct to rapidly diagnose immediate life-threatening injuries. Computed tomography (CT) and magnetic resonance imaging (MRI) later became additional imaging modalities important for injury diagnosis and management. By the early 90s, bedside abdominal examination with Focused Assessment with Sonography in Trauma (FAST) largely replaced diagnostic peritoneal lavage as the primary imaging modality for rapid assessment of intra-abdominal hemorrhage in unstable trauma patients.

This guideline is intended to assist trauma centers and their referring facilities to determine best practices to capture optimal imaging to diagnose injuries, while managing radiation exposure and avoiding potential adverse events associated with imaging. This document consolidates recommendations from existing guidelines of national organizations

and provides concise, evidence-based expert panel recommendations for practices to improve trauma patient imaging. Additionally, appropriate performance indicators are identified to guide the evaluation of imaging services in your trauma center. See the appendix for definitions of terminology used in this Best Practices Guideline.

Important Note

The intent of the ACS Trauma Quality Improvement Program (TQIP) Best Practices Guidelines is to provide health care professionals with evidence-based recommendations regarding care of the trauma patient. The Best Practices Guidelines do not include all potential options for prevention, diagnosis, and treatment and are not intended as a substitute for the provider's clinical judgment and experience. The responsible provider must make all treatment decisions based upon his or her independent judgment and the patient's individual clinical presentation. The ACS and any entities endorsing the Guidelines shall not be liable for any direct, indirect, special, incidental, or consequential damages related to the use of the information contained herein. The ACS may modify the TQIP Best Practices Guidelines at any time without notice.



1. OVERVIEW

Part 1: General Issues

Key Points

- Chest and pelvic radiographs continue to be a primary adjunct to diagnose immediate threats to life related to breathing and hemorrhage in the chest and/or extraperitoneal pelvis.
- A best practice is concurrent trauma evaluation and radiograph interpretation to facilitate timely treatment interventions for patients with severe injuries.
- Definitive imaging of complex vascular injuries ideally requires at least a 64-channel scanner to perform high quality vascular CT arteriography with three-dimensional (3D) reconstruction.
- Provide injury descriptors in radiologic reports to enable American Association for the Surgery of Trauma (AAST) organ injury scale (OIS) grading and trauma injury severity score determination.

Radiographic Imaging

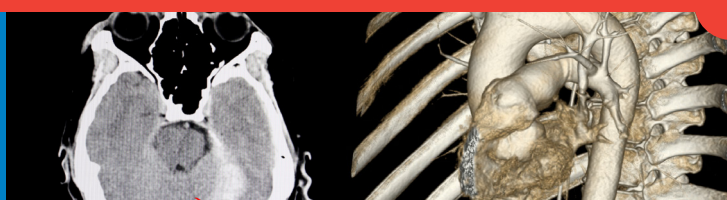Conventional torso radiographic imaging is a primary adjunct to rapidly facilitate the diagnosis of immediate threats to life related to breathing and hemorrhage in the chest (chest radiograph) and/or extraperitoneal pelvis (pelvis radiograph). These radiographs allow the treating

physician to expeditiously assess for, and immediately intervene in, life-threatening conditions such as cardiac tamponade, pneumothorax, or hemothorax. Perform a chest radiograph in all trauma patients with potential for thoracic injury and for evaluation of any tubes and lines placed during resuscitation. In the experienced provider's hands, FAST may have sensitivities higher than a conventional chest radiograph for pneumothorax and hemothorax.¹ Extremity radiographs remain an important secondary adjunct for diagnosis of extremity orthopaedic injury. A best practice is interpretation of all radiographs concurrent with the trauma evaluation to facilitate timely treatment interventions.

Computed Tomography Imaging

Multi-detector computed tomographic (MDCT) imaging is now well established as the imaging modality of choice in hemodynamically stable patients following the secondary survey exam. Oral contrast is not necessary in abdominopelvic MDCT for blunt trauma; however, IV contrast is required for visceral and vascular enhancement to identify visceral injury and vascular hemorrhage. Oral contrast may be beneficial in penetrating thoracoabdominal trauma to distend the esophagus and stomach if this is of clinical concern.

Each center needs MDCT trauma protocols for each body region. Optimal diagnostic abdominopelvic MDCT for trauma includes IV contrast. Delayed scans are performed selectively when the initial scan is positive or inconclusive for the purpose of:



- Evaluating collecting system rupture in the setting of renal trauma, or
- Evaluating for active bleeding and formation of hematomas.

Delayed scans are focused on the area of interest and are performed with a lower dose than the initial scan.

MDCT must be readily available 24/7/365 in trauma centers. Technology advances have reduced acquisition times and improved image quality.

Consequently, MDCT has replaced conventional diagnostic angiography, eliminating delays associated with mobilizing personnel for these procedures.^{2,3} Utilization of whole-body MDCT imaging of the head, neck, and torso facilitates rapid and comprehensive injury identification in the patient with multiple injuries, allowing optimal sequencing of treatment for patients with competing priorities. Providers must pay appropriate attention to safety issues of radiation exposure, patient monitoring, and ongoing resuscitation during image acquisition. Finally, providers must avoid the pitfall of over-utilizing MDCT imaging to definitively identify the source of hemorrhage already confirmed from previously performed images and avoid delay in operative hemorrhage control.

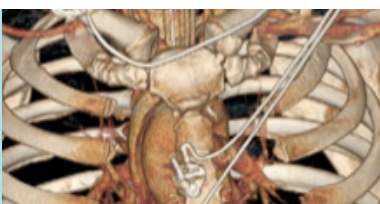
Incorporate all the following principles for best practice trauma MDCT acquisition:

- Have the MDCT scanner physically located as close to the trauma bay as possible;

- Make MDCT imaging available 24/7/365 with trauma patient priority access to the scanner before patients with non life-threatening conditions;
- Prioritize and expedite radiologic interpretation with immediate communication of life-threatening and emergent findings in a closed loop fashion to facilitate immediate treatment decision-making.

The critical importance and ultimate impact of a real-time collaborative availability of the interpreting radiologist in severely injured patients cannot be overstated.

Include injury descriptors needed to appropriately determine AAST organ injury scale (OIS) grading and trauma injury severity score determination for radiologic reporting.⁴ For rib fractures, the radiologist needs to report the number of rib fractures, location of rib fractures, and if flail rib fractures are noted. For liver injuries, the radiologist needs to specify the size of the hematoma and/or laceration, proportion of the lobe involved, and presence or absence of vascular injury. For spleen injuries, the radiologist needs to specify the size of the hematoma and/or laceration, proportion of spleen involved and presence or absence of vascular injury. For kidney injuries, the radiologist needs to specify the size of the hematoma and/or laceration, involvement of the renal cortex and collecting system, and presence or absence of vascular injury or urinary extravasation.



Include in the radiologic report all injuries with specific reference to any relevant life-threatening injuries in the summary findings. See Table 1 for essential components for optimal enhanced radiologic reporting on trauma CT scans.

MDCT imaging technology continues to rapidly evolve. Trauma centers and referring facilities need to continuously re-evaluate their protocols and capability to ensure imaging technology meets their needs. A radiologist liaison for

Table 1. Components of Enhanced Radiologic Reports for Trauma Injuries

Element	Description
Clinical history	Mechanism of injury
	Glasgow Coma Scale score, if applicable
	Abnormal physical and clinical findings, any deformities
	Specific clinical questions or concerns
Technique	Relevant history
	CT scans – unenhanced areas (in other words, CT head, CT face, CT cervical spine)
	CT scans – computed tomography angiography (CTA) parts and timing, if applicable
	CT scans – venous phase parts
	CT scans – delayed scanning, if applicable, region and timing
	CT cystogram – volume instilled, if applicable
	Iodinated contrast – type and amount
	Include whether oral and/or rectal contrast was used
	Precise body region scanned and two-dimensional (2D) reformations, 3D reconstructions
Other: Any deviation from standard protocol	
Other: Any contrast reaction	
Comparison	Include dates and outside facility, if applicable
Findings	Top to bottom anatomic approach
	Description and AAST grade for solid and hollow injuries
	Describe vascular injuries
Impression	Incidental CT findings
	Clear identification of study as normal versus abnormal
	Interpretation of findings, with AAST grade and vascular injuries
	Succinct differential diagnosis provided, if applicable
	Recommendations for follow up studies, if applicable
	Documentation of emergent findings in communication to referring physician or surrogate

Courtesy of Mark Bernstein, MD



trauma is essential for this purpose, and this representative needs to be well acquainted with evolving trauma patient care to match technological capability to trauma center objectives. Trauma and emergency radiology is an emerging radiologic subspecialty. Tertiary trauma centers are increasing the number of radiologic providers with dedicated fellowship training and/or subspecialty experience. These providers have potential to improve care by optimizing image acquisition and interpretation in the setting of trauma. They function as an immediate point of care contact to reduce time to treatment decision-making.

Minimum acceptable MDCT imaging technology for a given facility will depend on the goals for definitive treatment (in other words, if the patient with major injuries will be transferred to a higher level trauma center). Important aspects of imaging technology include the ability to acquire multiphasic examinations with a single contrast bolus, image quality, and the speed of image acquisition and post-processing. Appropriate and complete trauma MDCT protocols permit more accurate and rapid interpretation. In general, Level I and II trauma centers planning to perform definitive care of complex vascular injuries ideally need a 64-channel scanner to perform high quality vascular CTA with 3D reconstruction.^{5,6} Routine head, neck, and torso imaging, needed by other facilities to help with transfer decision-making, can adequately be performed on most CT scanners currently in use with 16 or more channels.

Radiation Exposure

Radiation exposure remains a factor in determining the best utilization of MDCT imaging. MDCT technology dose-adjusting software, based on body region, patient body habitus, and iterative reconstruction methodologies, has reduced radiation exposure significantly on modern scanners. The potential deleterious impact of radiation exposure is of greatest concern for pediatric and pregnant patient populations. Close cooperation with the radiologist for proper technique adjustment is encouraged. Expert consensus currently does not specify a definitive lifetime risk for malignancy, though it is likely to be exceedingly small.^{7,8} Providers need to understand this issue and balance the diminutive risk of exposure against the risk from potential missed or delayed diagnosis. Bedside ultrasound is a portable non-ionizing imaging modality with limited utility in the stable trauma patient, but may be helpful in the unstable patient. Alternative non-ionizing imaging modalities such as MRI also carry significant inherent risks including: remote transport for imaging, frequent requirement for sedation, limited availability for patient monitoring and resuscitation, and longer acquisition times. See acr.org/Quality-Safety/Appropriateness-Criteria for regularly updated consensus estimates of exposure and risk. Updated radiology safety exposure information for patients is available at radiologyinfo.org/en/submenu.cfm?pg=safety. It is critical that each facility's radiation safety program



inspect protocols and scanners at least annually to verify that radiation exposure levels are within national standards.

Part 2: Contrast Considerations

Key Points

- Use intravenous (IV) contrast for CT imaging when a visceral or vascular injury potentially exists.
- Risks associated with IV contrast include contrast extravasation, contrast allergy, and contrast nephropathy.
- Contrast allergic reaction can be attenuated or prevented with steroid pre-treatment protocols. Multiple oral doses or IV steroid a minimum of 4 hours prior to contrast infusion are most often prescribed.
- Patients particularly susceptible to acute contrast nephropathy include those with a significantly compromised glomerular filtration rate (GFR) because of multiple comorbidities, marked dehydration, or known chronic kidney injury.

IV contrast is utilized in all situations having a potential for visceral or vascular injury. Its use is critical for determination of active ongoing bleeding (contrast blush) and at-risk lesions such as pseudo-aneurysm or dissection. IV contrast greatly increases sensitivity of detecting solid organ injuries. Arterial phase imaging in conjunction with venous phase

acquisition facilitates differentiation between arterial and venous injuries that can impact treatment interventions.

IV contrast carries potential risks including contrast extravasation, contrast allergy, and contrast nephropathy. Contrast extravasation is the most frequent adverse risk related to contrast utilization, with a rate of approximately 0.26 to 0.7 percent.¹⁴⁻¹⁶ Significant morbidity is infrequent, with most adverse events occurring in patients with severe cachexia or impaired venous or lymphatic drainage.¹⁶ Most cases do not require significant intervention, with 97.4 percent having minimal to no adverse effects.¹⁵

IV contrast is most frequently administered through a pressure injector for optimal diagnostic clarity. Antecubital or large forearm venous injection sites are preferred to reduce risk of contrast extravasation, but exceptions can be made for patients with difficult access, as is often the case in seriously injured patients.¹⁷ When a large bore peripheral IV catheter cannot be obtained, a pressure rated central venous catheter designed to accommodate high-pressure injection (consult the package insert for each brand for further clarification) is a safe alternative.¹⁷ A central 9 Fr venous catheter is commonly placed in such patients and can be used, although many currently available products are not yet pressure rated. The large diameter of such cannulas can accommodate high flow rates while generating very low pressures. These products are commonly used despite their lack of pressure rating when no other expeditious

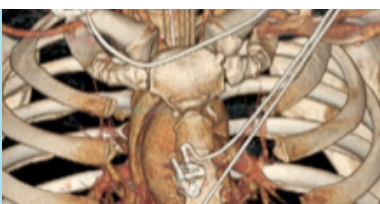


option exists. Intra-osseous injection is another alternative with demonstrated feasibility in several case reports.¹⁷⁻²¹

Contrast allergy, though rare with modern non-ionic formulations, carries a risk of anaphylactic reaction. Severe reactions occurred in 0.04 to 0.22 percent of studies performed.^{22,23} Visipaque[®] is reported to be the least allergenic formulation.²⁴ While a seafood allergy is commonly thought to place the patient at increased risk for anaphylactic contrast allergy, multiple studies do not demonstrate this.^{25,26} Patients with atopic tendencies carry no direct risk for anaphylaxis associated with non-ionic contrast. Patients with a history of previous contrast allergy have the highest risk for allergic reaction, however this is not an absolute contraindication to the use of IV contrast. Contrast reaction can be attenuated or prevented with steroid pre-treatment protocols in such patients, although evidence of the pre-treatment effectiveness is not conclusive.²² Most protocols prescribe multiple doses of oral or IV steroids a minimum of 4 hours prior to image acquisition and contrast infusion.²⁷ Though effective, these protocols have potential to result in significant delays in diagnosis. Consider unenhanced CT to look for fluid, air, and fractures when risk for further delay to definitive study with IV contrast is deemed prohibitive. It is unlikely that pre-treatment administered at less than 4-hour intervals will be effective.²⁸ See the American College of Radiology's Manual on Contrast Media at acr.org/Clinical-Resources/Contrast-

Manual, for regularly updated consensus guidelines on the safe utilization of oral and intravascular contrast media.

Contrast nephropathy is a significant concern when considering use of IV contrast for CT imaging. Overall, the risk of acute kidney injury (AKI) following IV contrast utilization is very low, ranging from 0 to 11 percent.^{29,30} Improved sensitivity of the study will outweigh AKI risk in the majority of patients.³¹ Patients with a significantly compromised glomerular filtration rate (GFR) because of multiple comorbidities, marked dehydration, or known chronic kidney injury are particularly susceptible to acute contrast nephropathy. Point-of-care creatinine assessment (iSTAT), when available, will rapidly estimate GFR in 2 minutes.³² Patients with a GFR of less than 30 mL/min are deemed at risk for AKI.³³ Options in these patients include performing the study initially without contrast or performing the study with the minimum acceptable volume contrast infusion necessary to obtain a diagnostic study. In patients where initial non-contrast torso imaging is utilized, real-time interpretation concurrent with acquisition is a best practice. The presence of mediastinal, intraperitoneal or retroperitoneal fluid consistent with hemorrhage (in other words, Hounsfield units of 30 or more), and/or concern for visceral injury usually warrants utilization of IV contrast despite its risk. In such circumstances, repeat imaging with IV contrast while the patient is still on the table can be performed minimizing treatment



delay and definitively identifying presence or absence of ongoing bleeding that warrants intervention.

Part 3: Sedation

Key Points

- Agitated adult trauma patients may require intubation with sedation and chemical paralysis to expedite radiographic work-up and ensure adequate quality. Short acting drugs are preferred along with careful monitoring of cardiac and respiratory status.
- Consider physiologic parameters (heart rate, blood pressure, and other existing injuries) and the child's age, size, and cognitive level to provide safe sedation administration.
- Patient age and cognitive developmental stage can significantly affect the amount and type of sedation administered.
- A dedicated provider and resuscitation equipment must be with the sedated patient at all times.

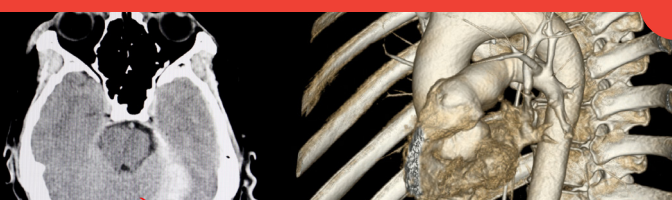Sedation for Adult Patient Imaging

Adult trauma patients may require light to moderate sedation to obtain adequate CT and MRI images. Agitated patients may require intubation with sedation and chemical paralysis to expedite radiographic work-up and to ensure adequate images. Short acting intravenous drugs are preferred with close monitoring of the patient's

hemodynamic and respiratory status.^{34,35} Be cautious when Haloperidol is used in the brain-injured patient because it decreases the threshold for seizures.³⁶ Haloperidol also has a FDA black box warning of increased mortality in the elderly patient with dementia related to psychosis.³⁶ In less urgent situations, MRI scanning of the patient who is not intubated may require deep sedation or light anesthesia with the presence of an anesthesiologist to assure the acquisition of adequate images.³⁷

Sedation for Pediatric Patient Imaging

Evaluating the pediatric trauma patient requires expert physical examination and appropriate high-quality radiographic images. Performing these studies in children, particularly toddlers and younger elementary school age, can be challenging. Factors to consider when ordering imaging studies in children include fear, loud noises, enclosed spaces, length of time to perform the study, and the need to minimize motion artifact. Sedation is often required to manage these challenges. Depending on the study needed, the depth and length of the sedation must be tailored. In addition to age, size, and cognitive level of the child, remember that physiologic parameters, including heart rate, blood pressure, and other existing injuries can complicate safe sedation administration.^{12,13} Also assume that the pediatric trauma patient has a full stomach because the time since last food or fluid intake cannot be determined in the emergent setting.



The use of skilled child life specialists to help minimize the injured child's fear and anxiety can markedly reduce the amount of sedation required. Their liberal use is recommended when available.

Pediatric Considerations for Specific Imaging Studies: Computed Tomography

Sedation is generally not required because of brevity of the imaging study. Children already intubated may require sedation for safety while travelling to the CT scanner.

MRI

The length of exam, noise, and motion artifact all contribute to a usual requirement for sedation in the pediatric patient, particularly those less than 5-years of age. When feasible consider using the "feed and sleep" technique in infants. When available, use child-life specialists with young children to attempt imaging without sedation.

Ensure that qualified personnel remain with the patient throughout the imaging study because of the long MRI tunnel, limited access to the patient, and specialized resuscitation equipment needed that is safe to use in the MRI suite. Ensure that ECG leads and other monitoring equipment is MRI compatible.^{9,10,11}

Interventional Radiology

Consider the following factors that may contribute to the use of deeper sedation or intubation in the young child to enable airway control and aggressive resuscitation in the event of cardiac arrest:^{12,13}

- Length of procedure
- Frightening environment for small children
- Cold temperatures
- Sterile environment that obscures the patient with sterile drapes/towels, equipment
- Potential hemodynamic instability

Most patients will require some degree of sedation during an interventional radiologic procedure. Only mild sedation is needed by the older child and adolescent. A dedicated provider and readily available resuscitation equipment must be with the patient at all times.

Guidelines for Use of Sedation

When the child requires sedation, experienced personnel with credentials to administer it are recommended. Patient age and cognitive developmental stage can significantly affect the amount and type of sedation administered. In patients with traumatic brain injury, the avoidance of hypotension from sedation is paramount. See Table 2 for emergency equipment needed for sedation patient monitoring in radiology suites.

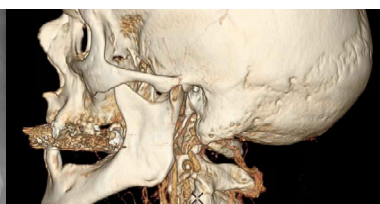
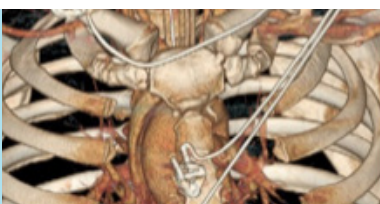


Table 2. Equipment and Emergency Medications Needed for Sedation Administration

Circumstances	Supplies Needed
Essential for all radiology suites	Emergency airway equipment Laryngoscopes Endotracheal tubes (all sizes) Laryngeal mask airway or similar device Oral airways Ambu bags Oxygen masks and tubing Pulse oximetry Telemetry
Additional equipment for traumatic brain injury or potential hypotension	Electrocardiogram monitoring Blood pressure monitoring Capnography Suction devices
Emergency medications	Epinephrine Atropine Succinylcholine Benadryl Solumedrol

Source: Langan ML, Mallory MM, & Herzog JM. Physiologic monitoring practices during pediatric procedural sedation, A Report From The Pediatric Sedation Research Consortium. *Arch Pediatr Adolesc Med.* 2012; 166(11): 990-998; Mason K, Zgleszewski S, & Holzman RS. Anesthesia and sedation for procedures in radiology. In: Motoyama E, & Davis P, *Smith's Anesthesia for Infants and Children, 7th ed.* St. Louis, MO: Mosby; 2006:1304; and American Academy of Pediatric Dentistry and American Academy of Pediatrics. Guideline for monitoring and management of pediatric patients before, during, and after sedation for diagnostic and therapeutic procedures: Update 2016. *Pediatrics.* 2016;138(1): e20161212.

Sedation Regimen Principles

Various published regimens for sedation, based on provider preference and facility-generated guidelines exist.³⁸ Facilities and trauma centers need to develop sedation practices that meet the needs of their patients and the skill of their providers. Basic practices and principles important for developing a facility-specific regimen for pediatric sedation needs to include the intended

level of sedation (in other words, minimal sedation, moderate sedation, deep sedation and general anesthesia), personnel and equipment required, monitoring and documentation.¹¹ See Table 3 for the classes of medications approved for sedation in children.



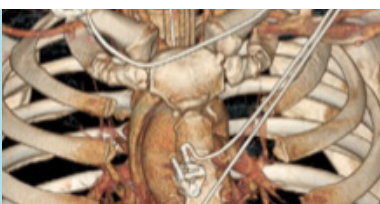
Table 3. Classes of Medications Approved for Sedation in Children

Medications	Considerations for Use
Benzodiazepines	<ul style="list-style-type: none"> • Efficacious in children, both anxiolytic and amnestic. • Onset of up to 20 minutes and duration up to 2 hours. • No analgesic effect, so if pain is anticipated, provide additional medications.
Opioids	<ul style="list-style-type: none"> • Usually administered in combination with a sedative. • Choose the agent based on length of time anticipated for study. • Fentanyl and remifentanyl have the most rapid action. Morphine and dilaudid are approved for use in children, but have a longer half-life.
Ketamine	<ul style="list-style-type: none"> • Neuroprotective in children with head injury. • It does not diminish the respiratory drive, and it is less likely to produce hypotension.
Dexmedetomidine	<ul style="list-style-type: none"> • Safe for use in children. • Provides mostly sedative effects with minimal analgesia. • Does not affect the respiratory drive, but may produce hypotension.
Propofol	<ul style="list-style-type: none"> • Safe for use in children for brief periods. • Not recommended as continuous infusion. • Rapid onset and rapid clearance • Neuroprotective effects

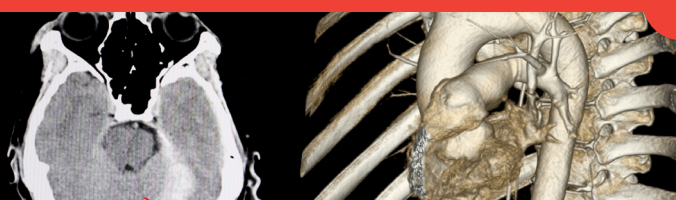Source: Kahl L, Hughes H. *The Harriet Lane Handbook*, 21st Ed. St. Louis, MO: Elsevier; 2017; Mason K, Zgleszewski S, Holzman RS. Anesthesia and sedation for procedures in radiology. In: Motoyama E, & Davis P, *Smith's Anesthesia for Infants and Children, 7th ed.* St. Louis, MO: Mosby; 2006: 1304.

References

1. Christie-Large M, Michaelides D, James S. Focused assessment with sonography for trauma: the FAST scan. *Trauma*. 2008; 10(2): 93-101.
2. Peng PD, Spain DA, Tataria M, Hellinger JC, Rubin GD, Brundage SI. CT angiography effectively evaluates extremity vascular trauma. *Am Surg*. 2008; 74(2): 103-107.
3. Busquéts AR, Acosta JA, Colón E, Alejandro KV, Rodríguez P. Helical computed tomographic angiography for the diagnosis of traumatic arterial injuries of the extremities. *J Trauma Acute Care Surg*. 2004; 56(3): 625-628.
4. Association for the Advancement of Automotive Medicine. *AIS Abbreviated Injury Scale, 2015*, Retrieved from <https://www.aaam.org/ais-2015-released/>, Accessed August 3, 2018.
5. Kertesz JL, Anderson SW, Murakami AM, Pieroni S, Rhea JT, Soto JA. Detection of vascular injuries in patients with blunt pelvic trauma by using 64-channel multidetector CT. *RadioGraphics*. 2009; 29(1): 151-164.
6. Rogalla P, Kloeters C, Hein PA. CT technology overview: 64-slice and beyond. *Radiol Clin N Am*. 2009; 47(1): 1-11.
7. McCollough CH, Bushberg JT, Fletcher JG, Eckel LJ. Answers to common questions about the use and safety of CT scans. *Mayo Clin Proc*. 2015; 90(10): 1380-1392.
8. Schauer DA, Linton OW. National Council on Radiation Protection and Measurements report shows substantial medical exposure increase. *Radiology*. 2009; 253(2): 293-296.
9. Wellis VM. *Pediatric Anesthesia and Pain Management Practice Guidelines for the MRI and MRT*. Palo Alto: Lucile Packard Children's Hospital, Stanford University Medical Center, Department of Anesthesia and Pain Management. Available at: <http://med.stanford.edu/content/dam/sm/pedsanesthesia/documents/mri.pdf>. Published 1998, Accessed April 12, 2018.
10. Schulte-Uentrop, L., & Goepfert, M. S. (2010). Anaesthesia or sedation for MRI in children. *Current Opinion in Anaesthesiology*, 2010;4:513-7. doi.10.1097/ACO.0b013e32833bb524.
11. American Academy of Pediatric Dentistry and American Academy of Pediatrics. Guideline for monitoring and management of pediatric patients before, during, and after sedation for diagnostic and therapeutic procedures: Update 2016. *Pediatrics*. 2016; 138(1): e20161212
12. Langan, ML, Mallory, MM, & Herzog, JM. Physiologic monitoring practices during pediatric procedural sedation, A report from the Pediatric Sedation Research Consortium. *Arch Pediatr Adolesc Med*. 2012; 166(11): 990-998. doi.10.1001/archpediatrics.2012.1023



13. Mason K, Zgleszewski S, & Holzman RS. Anesthesia and sedation for procedures in radiology. In: Motoyama E, & Davis P, *Smith's Anesthesia for Infants and Children, 7th ed.* St. Louis, MO: Mosby; 2006: 1304
14. Behzadi AH, Farooq Z, Newhouse JH, Prince MR. MRI and CT contrast media extravasation: A systematic review. *Medicine* (Baltimore). 2018 Mar; 97(9):p e0055. doi:10.1097/MD.00000000000010055.
15. Wang CL, Cohan RH, Ellis JH, Adusumilli S, Dunnick NR. Frequency, management, and outcome of extravasation of nonionic iodinated contrast medium in 69,657 intravenous injections. *Radiology*. 2007; 243(1): 80-87.
16. Tonolini M, Campari A, Bianco R. Extravasation of radiographic contrast media: Prevention, diagnosis, and treatment. *Curr Probl Diagn Radiol*. 2012; 41(2): 52-55.
17. American College of Radiology. *ACR Manual on Contrast Media*. 2015. Available at: <https://www.acr.org/Clinical-Resources/Contrast-Manual>. Accessed April 15, 2018.
18. Plancade D, Nadaud J, Lapiere M, et al. Feasibility of a thoraco-abdominal CT with injection of iodinated contrast agent on sternal intraosseous catheter in an emergency department. *Ann Fr Anesth Reanimation*. 2012; 31(12): e283-284.
19. Cambray EJ, Donaldson JS, Shore RM. Intraosseous contrast infusion: Efficacy and associated findings. *Pediatric Radiol*. 1997; 27(11): 892-893.
20. Ahrens KL, Reeder SB, Keevil JG, Tupesis JP. Successful computed tomography angiogram through tibial intraosseous access: A case report. *J EmergMed*. 2013; 45(2): 182-185.
21. Knuth TE, Paxton JH, Myers D. Intraosseous injection of iodinated computed tomography contrast agent in an adult blunt trauma patient. *Ann Emerg Med*. 2011; 57(4): 382-386.
22. Tramer MR, von Elm E, Loubeyre P, Hauser C. Pharmacological prevention of serious anaphylactic reactions due to iodinated contrast media: Systematic review. *BMJ (Clinical research ed)*. 2006; 333(7570): 675.
23. Katayama H, Yamaguchi K, Kozuka T, Takashima T, Seez P, Matsuura K. Adverse reactions to ionic and nonionic contrast media. A report from the Japanese Committee on the Safety of Contrast Media. *Radiology*. 1990; 175(3): 621-628.
24. Cochran ST, Bomyea K, Sayre JW. Trends in adverse events after IV administration of contrast media. *Am J Roentgenol*, 2001; 176: 1385-1388.
25. Schabelman E, Witting M. The relationship of radioccontrast, iodine, and seafood allergies: A medical myth exposed. *J Emerg Med*. 2010; 39(5): 701-707.
26. Baig M, Farag A, Sajid J, Potluri R, Irwin RB, Khalid HM. Shellfish allergy and relation to iodinated contrast media: United Kingdom survey. *World J Cardiol*. 2014; 6(3): 107-111.
27. Lasser EC, Berry CC, Mishkin MM, Williamson B, Zheutlin N, Silverman JM. Pretreatment with corticosteroids to prevent adverse reactions to nonionic contrast media. *Am J Roentgenol* 1994 Mar; 162(3):523-526.
28. American College of Radiology. *ACR Manual on Contrast Media*, Version 10.3, 2017: 9-11. Retrieved from <https://www.acr.org/Clinical-Resources/Contrast-Manual>, Accessed August 3, 2018.
29. Weisbord SD, Hartwig KC, Sonel AF, Fine MJ, Palevsky P. The incidence of clinically significant contrast-induced nephropathy following non-emergent coronary angiography. *Catheterization and Cardiovascular Interventions*. 2008; 71(7): 879-885.
30. Weisbord SD, Mor MK, Resnick AL, Hartwig KC, Palevsky PM, Fine MJ. Incidence and outcomes of contrast-induced AKI following computed tomography. *CJASN*. 2008; 3(5): 1274-1281.
31. Kim DY, Kobayashi L, Costantini TW, et al. Is contrast exposure safe among the highest risk trauma patients? *J Trauma Acute Care Surg*. 2012; 72(1): 61-66; discussion 66-67.
32. I-STAT. Creatinine Package Insert. In: I-STAT, ed 2003: 1-5.
33. Owen RJ, Hiremath S, Myers A, Fraser-Hill M, Barrett BJ. Canadian Association of Radiologists consensus guidelines for the prevention of contrast-induced nephropathy: Update 2012. *Can Assoc Radiol J*. 2014; 65(2): 96-105.
34. Oddo M, Crippa IA, Mehta S, et al. Optimizing sedation in patients with acute brain injury. *Crit Care*. 2016; 20:128. https://www.ncbi.nlm.nih.gov/pmc/articles/PMC4857238/pdf/13054_2016_Article_1294.pdf. Accessed April 15, 2018.
35. Williamson DR, Fremette AK, Burry L, et al. Pharmacological interventions for agitation in patients with traumatic brain injury: Protocol for a systematic review and meta-analysis. *Syst Rev*. 2016; 5: 193. <https://systematicreviewsjournal.biomedcentral.com/articles/10.1186/s13643-016-0374-6>
36. Haldol, increased mortality in elderly patients with dementia-related psychosis. <https://www.drugs.com/pro/haldol.html#s-34066-1>; Accessed April 4, 2018.
37. Practice Advisory on Anesthetic Care for Magnetic Resonance Imaging. An updated report by the American Society of Anesthesiologists Task Force on Anesthetic Care for Magnetic Resonance Imaging. *Anesthesiology*. 2015; 122(3): 495-520.
38. Mahajan C, Dash HH. Procedural sedation and analgesia in pediatric patients. *J Pediatr Neurosci*. 2014; 9(1): 1-6.



2. BRAIN IMAGING

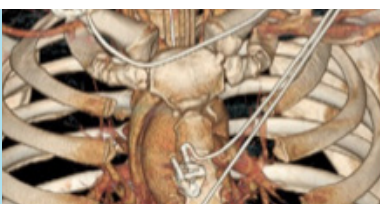
Key Points

- Adult trauma patients presenting with an altered or depressed mental status, a history of loss of consciousness, or significant post-traumatic amnesia need a head CT scan.
- A negative initial head CT scan in a patient not on anticoagulant therapy has a negative predictive value of greater than 99.97 percent for the need of any subsequent neurosurgical intervention, allowing safe discharge from the emergency department (ED).
- A repeat head CT is needed in 6-12 hours when a patient of any age has a persistently altered mental status. Urgent repeat head CT scanning is needed for the patient of any age with any worsening changes on neurologic exam.
- Patients with supra-therapeutic international normalized ratio (INR) or thrombocytopenia may benefit from repeat head CT, despite a normal initial head CT, if they take oral anticoagulant or antiplatelet drugs.
- Indications for head CT in children should follow the PECARN decision guide. Children with non-frontal soft tissue hematoma or brief loss of consciousness without other symptoms do not require a head CT.

Head CT scanning is the cornerstone of diagnosing traumatic brain injury (TBI), regardless of patient age, and CT findings play an integral role in dictating subsequent management. Unlike stroke or other central nervous system disorders, focal or discriminating neurologic findings on physical examination are the exception following TBI, placing even greater emphasis and importance on early CT scanning.

Initial Imaging

All patients presenting with an altered or depressed mental status in the setting of trauma need a head CT scan. In contrast, the decision to image is more challenging for the patient with suspected traumatic brain injury (TBI) who presents with a history of documented loss of consciousness (LOC) and/or post-traumatic amnesia, and now is awake and oriented. In the population of patients with minimal head injury as defined by a history of LOC and a GCS of 14–15, the incidence of positive head CT scans (defined as any type of intracranial bleed) is 10 to 15 percent.¹⁻³ Including patients with a GCS of 13 increases that to 15 to 20 percent. These data do not appear to be influenced by age; however, many studies excluded pediatric patients, and patients with pre-existing intracranial abnormalities or on anticoagulant therapy. Age greater than 65 years was an independent risk factor of having a positive head CT scan in the original derivation of the Canadian CT Head Injury Rule.⁴ Recent data examining this algorithm suggest that older patients have an increased risk of intracranial injury.⁵ More importantly from a management standpoint, the



liberal use of head CT scanning allows safe discharge from the trauma bay as a negative initial head CT scan in a patient not on anticoagulation has a negative predictive value of greater than 99.97 percent for the need for any subsequent neurosurgical intervention.¹

Repeat Imaging

While the population of patients who require an initial CT scan of the brain is defined, more controversy exists about patients who require repeat head CT scanning. Patients who sustained a minimal TBI (defined as initial GCS 13-15 and the presence of any intracranial injury on initial head CT imaging) and have either an improving or persistently normal mental status do not require a repeat head CT. In contrast, patients with a persistently altered mental status should undergo repeat CT in 6-12 hours. Any worsening of a patient's neurologic exam is an indication for urgent CT scanning, as soon as possible.⁶ For patients with more severe TBI (defined as an admitting GCS of 12 or less), insufficient data exist to identify patients who do not require a repeat CT. A second CT is almost always warranted because progression of injury is often not predictable or may be occult. The timing of the repeat CT is dependent upon the patient's neurologic status and findings on the first head CT scan, but the recommended timing is within the first 6-12 hours, if not sooner. These data and recommendations are not age restricted.

Anticoagulants

The use of anticoagulant therapy further complicates recommendations for brain imaging. During the initial trauma patient evaluation, often an incomplete list of prescribed medications or pre-existing comorbidities is known. The history may reveal that the patient takes "blood thinners," but it is not known which one(s) or why prescribed. Patients who know their medications may not have therapeutic levels. In addition, patients requiring anticoagulation often have dementia or other neurologic diagnoses that can influence and alter their baseline mental status and neurologic examination. For this group of patients, the incidence of intracranial bleeding is likely higher, and a more liberal use of early initial brain CT scanning is warranted.⁷ While many patients will have no injury, it is impossible to differentiate between patients with and without an intracranial injury without head CT imaging.

The recommendations for follow up imaging of patients on anticoagulant therapy are even less evidence based, and no published prospective, randomized controlled trials address this issue. Several factors, including the presence or absence of intracranial hemorrhage (ICH) on the initial CT, the type of pre-injury anticoagulant/antiplatelet agent used, and degree of drug-induced coagulopathy, are important elements to consider when making the decision to perform repeat head CT in this cohort of patients. Some patients are prescribed more than one agent, and many studies either fail



to differentiate the various agents or do not provide sufficient information to help make those determinations. Despite these limitations some simple recommendations exist to help guide decisions for imaging.

Several studies examined the incidence and outcomes of delayed ICH in patients on pre-injury oral anticoagulant or antiplatelet therapy with a negative initial head CT scan. Some retrospective study findings revealed that less than 1.5 to 2 percent of patients on pre-injury warfarin or aspirin developed delayed intracerebral bleeding, none of which required intervention.^{3,8,9} Studies examining individual oral anticoagulant or antiplatelet agents yield similar results. Patients taking warfarin who had supra-therapeutic INR levels (greater than 3) had an increased risk of developing a new bleed following an initial negative head CT. A recent meta-analysis of 1,594 patients on pre-injury warfarin with a normal initial head CT estimated a 0.6 percent pooled incidence of delayed ICH after 24 hours with a risk of neurosurgical intervention or death of 0.3 percent.¹⁰ These data suggest that a small number of positive head CT scans occur in patients using oral anticoagulants or antiplatelet agents who had an initial normal head CT scan. However, these findings are rarely associated with an increased risk of neurologic deterioration. Although the need for neurosurgical intervention is rare, no data exist to support discharging these patients from the ED based on a single head CT scan, unlike patients who are not on anticoagulation.

In patients on platelet inhibitors alone (aspirin, clopidogrel) more contradictory data have been reported. Many studies and algorithms considered aspirin to be a low-risk medication; however, recent data question that assertion.¹¹ In a prospective observational study of 265 patients with ICH on initial head CT, both aspirin and clopidogrel were identified as independent predictors of mortality and the need for neurosurgical intervention.¹² Moreover, clopidogrel had higher odds of worse outcomes compared with aspirin.¹² Thus, it is prudent to have a liberal policy of repeat head CT imaging for patients who have an initial positive head CT scan. In patients with a negative initial head CT scan and no other reason for hospital admission, a second head CT scan in 4-8 hours is prudent. If the patient is admitted for other reasons and serial mental status assessment will be performed, then repeat head CT imaging may not be necessary. Remember, a significant number of patients admitted for neurologic observation are incompletely observed, which favors a liberal policy of repeat head CT scanning.²

In summary, the role of repeat head CT in patients with TBI on pre-injury anticoagulant or antiplatelet therapy remains elusive. The available evidence suggests that patients on anticoagulant or antiplatelet agents with a normal INR and platelet count may not require repeat CT after a normal initial head CT scan. Patients with supra-therapeutic INR or thrombocytopenia may benefit from repeat CT, despite a normal initial head CT if they take oral anticoagulant or antiplatelet drugs.



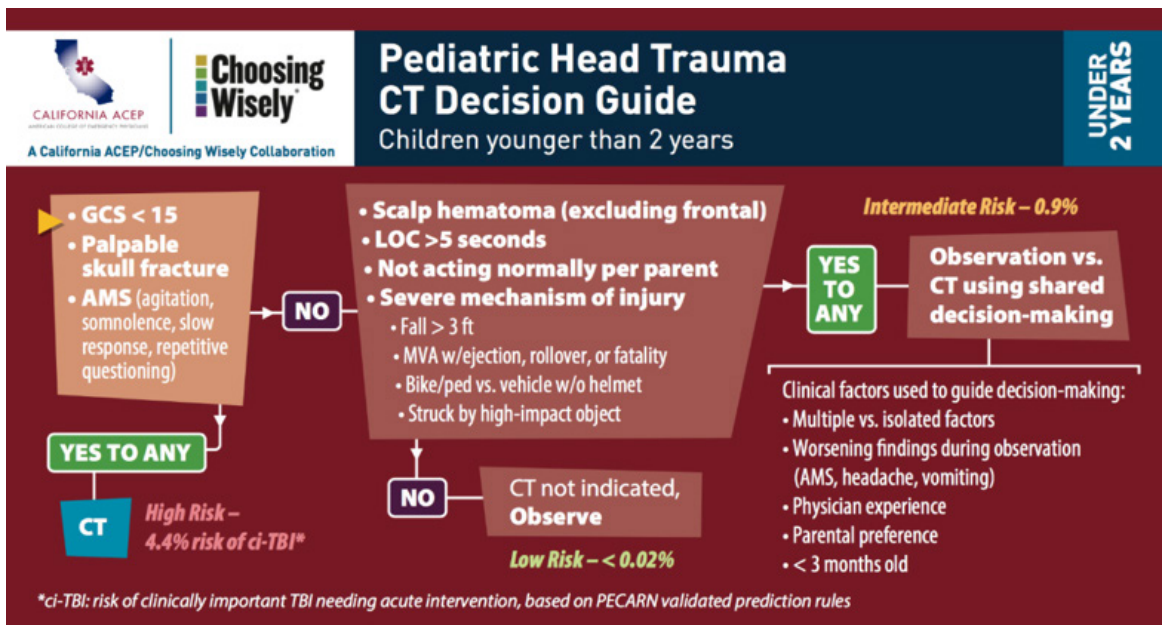
Insufficient data exist about the novel oral anticoagulants to make any firm recommendation about the need for repeat CT imaging, regardless of initial head CT scanning findings. Thus a liberal repeat head CT policy is warranted for this patient cohort as well.

Pediatric Patient Considerations

Decisions about appropriate use of ionizing radiation in children must be implemented. Evidence-based guidelines used to identify children at very low risk of clinically significant TBI were developed and validated by the Pediatric Emergency Care Applied Research Network (PECARN) and adopted

by the Choosing Wisely campaign.¹³ Specific clinical prediction pathways exist for children who are verbal (greater than 2 years old) and nonverbal (less than 2 years old) (see Figures 1 and 2). Children with nonfrontal soft tissue hematoma, brief loss of consciousness, or severe mechanism of injury without other clinical symptoms may undergo CT or observation, and that decision is based on clinical factors, patient age, physician experience, and parental preference. A brief observation period in the ED and discharge home with return precautions is a reasonable approach for children with reliable follow up mechanisms.

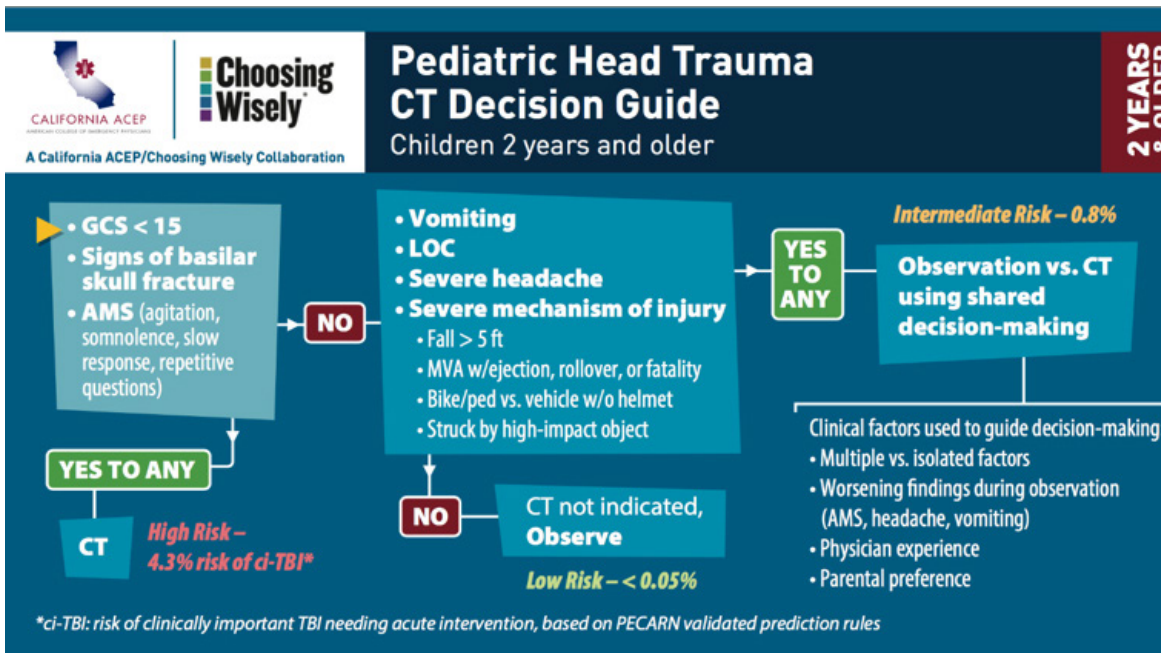
Figure 1. Pediatric Head Trauma CT Decision Guide for Children Younger than 2 Years



PECARN Decision Guide reprinted with permission from: California ACEP, American College of Emergency Physicians.



Figure 2. Pediatric Head Trauma CT Decision Guide for Children Ages 2 Years or Older

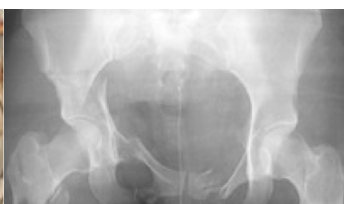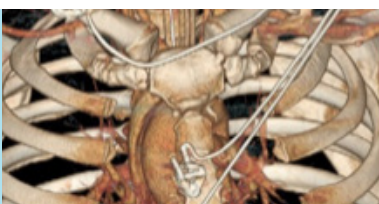


PECARN Decision Guide reprinted with permission from: California ACEP, American College of Emergency Physicians.

Additional efforts to decrease unnecessary radiation use in children focus on evaluating the need for routine repeat head CT. Routine repeat brain imaging is not necessary for all children with TBI. Growing evidence suggests reserving repeat head CT for patients with a decline in GCS score, worsening neurological examination, or in patients sedated for increased intracranial pressure (ICP) management who cannot be evaluated.¹⁴ Serial imaging decisions for individualized treatment pathways (for example, nonoperative management of posterior fossa epidural hematoma) are made by the neurosurgical team.

References

1. Livingston DH, Lavery RF, Passannante MR, et al. Emergency department discharge of patients with a negative cranial computed tomography scan after minimal head injury. *Ann Surg.* 2000; 232(1): 126-32. PubMed PMID: 10862205; PubMed Central PMCID: PMC1421117.
2. Shackford SR, Wald SL, Ross SE, et al. The clinical utility of computed tomographic scanning and neurologic examination in the management of patients with minor head injuries. *J Trauma.* 1992; 33(3): 385-94. PubMed PMID: 1404507.
3. Barbosa RR, Jawa R, Watters JM, et al. Evaluation and management of mild traumatic brain injury: An Eastern Association for the Surgery of Trauma practice management guideline. *J Trauma Acute Care Surgery.* 2012; 73(5): S307-S314.
4. Stiell IG, Wells GA, Vandemheen K, et al. The Canadian CT Head Rule for patients with minor head injury. *Lancet.* 2001 May5; 357(9266): 1391-6. PubMed PMID: 11356436.



5. Wolf H, Machold W, Frantal S, et al. Risk factors indicating the need for cranial CT scans in elderly patients with head trauma: An Austrian trial and comparison with the Canadian CT Head Rule. *J Neurosurg.* 2014; 120(2): 447-52. doi.10.3171/2013.10.JNS13726. Epub 2013 Dec 6. PubMed PMID: 24313609.
6. Sifri ZC, Homnick AT, Vaynman A, et al. A prospective evaluation of the value of repeat cranial computed tomography in patients with minimal head injury and an intracranial bleed. *J Trauma.* 2006; 61(4): 862-7. PubMed PMID: 17033552.
7. Brewer ES, Reznikov B, Liberman RF, et al. Incidence and predictors of intracranial hemorrhage after minor head trauma in patients taking anticoagulant and antiplatelet medication. *J Trauma.* 2011; 70(1): E1-5. doi.10.1097/TA.0b013e3181e5e286. PubMed PMID: 20693913.
8. Peck KA, Sise CB, Shackford SR, et al. Delayed intracranial hemorrhage after blunt trauma: are patients on preinjury anticoagulants and prescription antiplatelet agents at risk? *J Trauma.* 2011; 71(6): 1600-4. doi.10.1097/TA.0b013e31823b9ce1. PubMed PMID: 22182870.
9. Kaen A, Jimenez-Roldan L, Arrese I, et al. The value of sequential computed tomography scanning in anticoagulated patients suffering from minor head injury. *J Trauma.* 2010; 68(4): 895-898.
10. Chauny JM, Marquis M, Bernard F, et al. Risk of delayed intracranial hemorrhage in anticoagulated patients with mild traumatic brain injury: Systematic review and meta-analysis. *J Emerg Med.* 2016; 51(5): 519-528.
11. Kobayashi LM, Bukur M, Catalano RD, et al. There is nothing little about the impact of baby aspirin: The results of a prospective AAST multi-institutional trial of oral anticoagulants. Presented at AAST Waikoloa, HI 2016.
12. Joseph B, Pandit V, Meyer D, et al. The significance of platelet count in traumatic brain injury patients on antiplatelet therapy. *J Trauma Acute Care Surg.* 2014; 77(3): 417-421.
13. Kuppermann N, Holmes JF, Dayan PS, et al; Pediatric Emergency Care Applied Research Network (PECARN). Identification of children at very low risk of clinically-important brain injuries after head trauma: A prospective cohort study. *Lancet.* 2009; 374(9696): 1160-70. doi.10.1016/S0140-6736(09)61558-0. PubMed PMID: 19758692.
14. Hill EP, Stiles PJ, Reyes J, et al. Repeat head imaging in blunt pediatric trauma patients: Is it necessary? *J Trauma Acute Care Surg.* 2017; 82(5): 896-900. doi.10.1097/TA.0000000000001406. PubMed PMID: 28248802.



3. CERVICAL SPINE IMAGING

Key Points

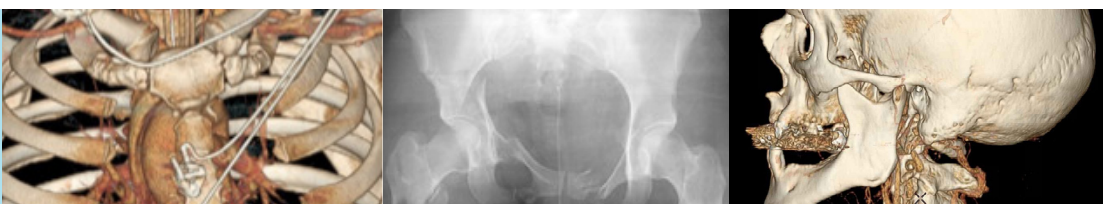- Use either the National Emergency X-Radiography Utilization Study (NEXUS) criteria or Canadian Cervical Rules (CCR) to guide imaging decisions for cervical spine evaluation in stable trauma patients where cervical spine injury is a concern; however, NEXUS and CCR criteria are not applicable for the pediatric patient or the older adult patient (55 years and older).
- Clinical decision rule criteria are less sensitive for older adults indicating a need for more liberal imaging decisions.
- MDCT is the preferred imaging for cervical spine fracture identification.
- Perform an MRI in patients with possible spinal cord injury; clinical concern for cord compression due to disk protrusion, hematoma, or unstable fracture pattern; or neck pain or tenderness out of proportion to the CT findings.
- A best practice is for each trauma center to develop a policy and performance improvement (PI) process regarding cervical collar removal and indications for performing a cervical spine MRI in the obtunded patient.

- The asymptomatic child with a reliable normal exam does *not* require imaging to clear the cervical spine, regardless of mechanism.

An estimated 3 to 4 percent of patients presenting to the ED with blunt trauma will sustain an injury to the cervical spine (C-spine).^{1,2} C-spine injuries range from stable minor soft tissue injuries to unstable complex injury patterns resulting in complete disruption of the C-spine with possible neurologic and/or vascular injury. The wide spectrum of injury patterns make the decision process challenging regarding when to image and what type of imaging to perform. Devastating clinical outcomes can result when a cervical vascular or unstable C-spine injury is not identified, leading to the practice of obtaining C-spine imaging in any patient with a remote possibility of injury. However, overutilization C-spine imaging has a cost: longer ED visits while awaiting imaging; prolonged cervical collar placement; exposure to radiation (radiographs and CT); risk of travel to and from the imaging area (especially for mechanically-ventilated patients in the MRI suite); and risk of general anesthesia for some patients requiring MRI.

Clinical Decision Rules

The NEXUS and the CCR are well-established clinical decision criteria for exclusion of clinically significant C-spine injury in stable, awake trauma patients. The original NEXUS criteria study reported a 99.6 percent sensitivity for detecting clinically significant cervical injury.³ The initial study of the CCR reported a 100 percent sensitivity for detecting clinically significant C-spine



injuries in alert patients (GCS = 15) and stable trauma patients.⁴ A review of 15 published studies reported the NEXUS sensitivity ranged from 0.83 to 1.00 and specificity ranged from 0.02 to 0.46, while the CCR sensitivity ranged from 0.90 to 1.00 and specificity ranged from 0.01 to 0.77.⁵ A study comparing the CCR and NEXUS criteria found that the CCR slightly outperformed NEXUS in selecting patients at risk for C-spine injury.^{5,6} However, multiple studies validated the sensitivity of both the NEXUS and CCR criteria for identifying clinically significant C-spine injuries.⁶⁻¹¹

Using one of these clinical decision rules is recommended to guide imaging decisions for C-spine evaluation in the awake, stable adult trauma patient (Table 4 and Figure 3). The NEXUS was formulated and validated when plain radiographs were commonly utilized to assess for C-spine injuries, causing some validity concern. CT imaging is now more common and much more sensitive for detecting C-spine injury than plain radiographs, and CT imaging may identify injuries that would be missed by the NEXUS and/or CCR criteria.

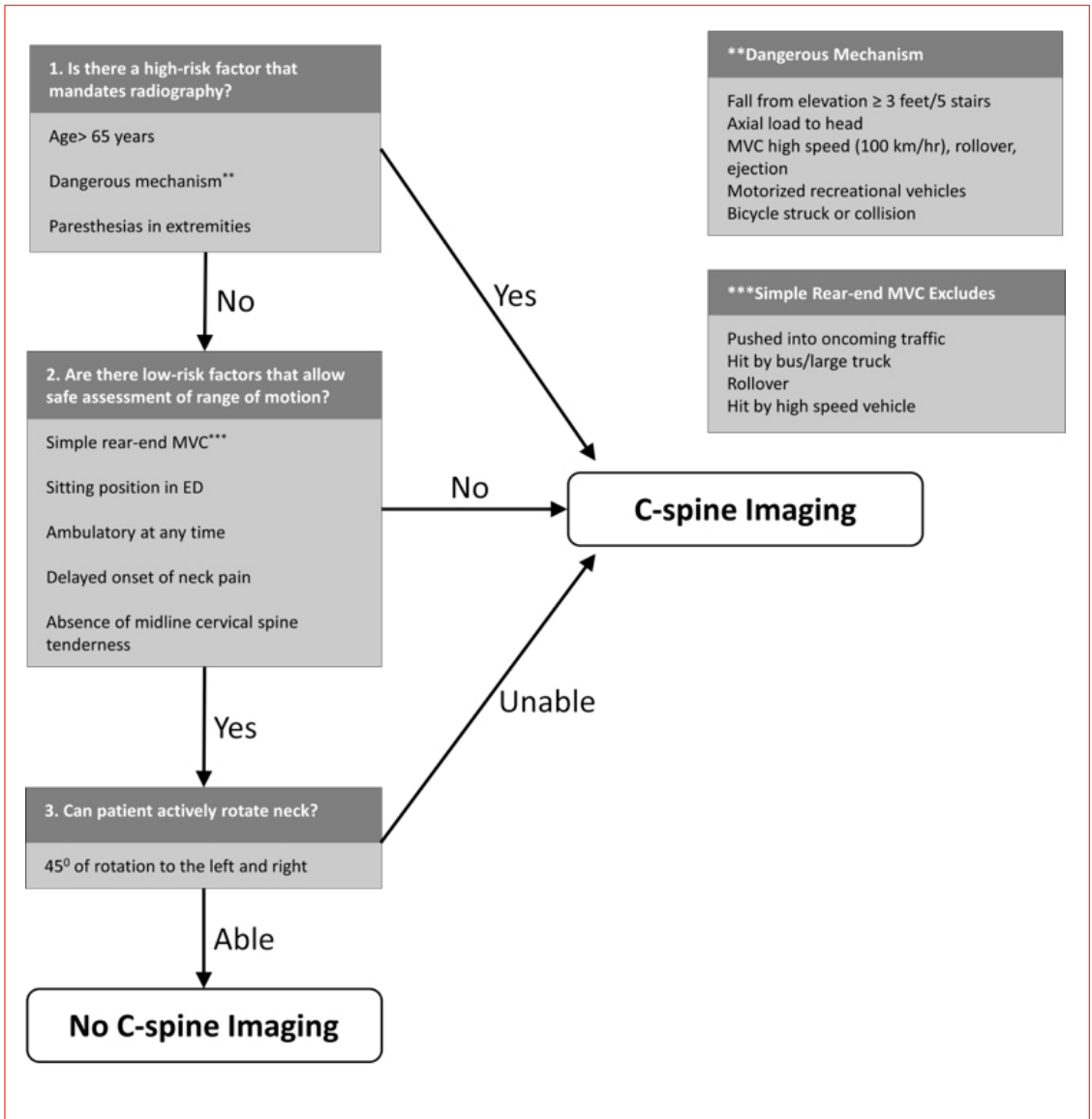
Table 4. NEXUS Criteria for Cervical Spine Imaging

NEXUS Criteria	Imaging Recommendation
Focal neurologic deficit	Imaging of the cervical spine is indicated if any of these findings are present
Midline spinal tenderness	
Altered level of consciousness	
Intoxication	
Distracting injury	

Source: Hoffman JR, Mower WR, Wolfson AB, Todd KH, Zucker MI. Validity of a set of clinical criteria to rule out injury to the cervical spine in patients with blunt trauma. National Emergency X-Radiography Utilization Study Group. *N Engl J Med.* 2000; 343(2): 94-99. Reprinted with permission.



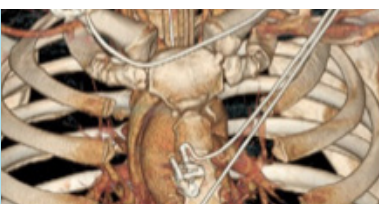Figure 3. Canadian Cervical Spine Rules*



***Only applies to stable trauma patients with a Glasgow Coma Score of 15.**

Source: Stiell IG, Wells GA, Vandemheen KL, et al. The Canadian C-spine rule for radiography in alert and stable trauma patients. *JAMA*. 2001; 286(15): 1841-1848. Reprinted with permission.





Evaluating the C-Spine in Special Populations!

Use extra caution when patients with severe injuries meet the Centers for Disease Control and Prevention (CDC) criteria for trauma team activation.¹⁰ These patients have at least a six-fold increase in risk for C-spine injury, and the NEXUS sensitivity is decreased substantially.^{12,13}

Caution is also needed in older adults. A study of older adult trauma patients (55 years or older) with C-spine fractures found that 21 percent were asymptomatic (did not complain of neck pain, denied tenderness on palpation of the C-spine, and had no neurologic deficits). The older adult with asymptomatic C-spine fractures required surgical intervention at a rate similar to the symptomatic group (19 vs. 22 percent).¹⁴ Published C-spine clearance guidelines may not be fully applicable in the older adults who sustain blunt trauma. A recent study reported that 21 of 468 adults 65 or older with C-spine fracture were NEXUS negative (maximum sensitivity 95.5 percent).¹⁵ Consider more liberal imaging in older adults.

The NEXUS and the CCR clinical decision criteria are intended for stable, awake trauma patients. Use MDCT screening for all patients with altered sensorium.

Initial Imaging

MDCT is the recommended imaging for C-spine fracture identification, outperforming radiographs in identification of C-spine fractures in high, moderate, and low risk stratifications.¹⁶ MDCT is inferior to MRI in the identification of many soft tissue injuries such as epidural hematoma, cord contusion, and ligament sprains.¹⁷⁻²³ Additionally less than 1 percent of patients who cannot be clinically examined have evidence of C-spine instability on MRI not appreciated on MDCT.^{18,19,24-30} Some authors find that MDCT is adequate for excluding clinically significant C-spine injury in patients without neurologic symptoms, even when neck tenderness is present.³¹ The Western Trauma Association Multi-Institutional Trial reported that CT was effective for ruling out clinically significant injury with a sensitivity of 98.5 percent. A

small, but a clinically significant incidence of a missed injury was noted, and further imaging with MRI is warranted.³²

Perform MDCT for evaluation of C-spine injury from the skull base through the cervicothoracic junction with thin (2 mm) reformatted images in axial, coronal, and sagittal planes. IV contrast does not aid in detection of C-spine injury. In most instances the cervical CT examination is performed in conjunction with a cranial CT, which saves time and is cost-effective.³³

When to Perform MRI

Perform an MRI in patients who have possible spinal cord injury and clinical concern for cord compression due to disk protrusion, hematoma, or fracture fragments. MRI is valuable



for characterizing the cause and extent of spinal cord injury, and it is complementary to CT. The severity of the injury (for example, extent of intramedullary hemorrhage, length of edema, severity of cord compression, and evidence of cord transaction) contribute to predicting neurologic outcome.³⁴ Compression of the cord by disk herniation, bone fragments, and hematomas is best displayed on MRI, and MR images are often used to guide surgical interventions.^{19,31}

MRI assessment of the discoligamentous complex integrity is a crucial component in preoperative assessment of the C-spine.^{35,36} Discoligamentous injury is invariably present in a mechanically unstable C-spine, and MRI is the recommended imaging for assessment of soft tissue injuries, including injury to the discoligament complex.^{17-21,23}

MRI can also identify soft tissue injuries frequently associated with C-spine instability, such as epidural hematoma and cord contusion needing surgical management. No widely accepted criteria exist for grading the severity of C-spine soft tissue injury on MRI. While MRI has a high sensitivity for identifying C-spine soft tissue injuries, its specificity for identifying clinically significant cervical soft tissue injuries is modest.³⁷ Therefore, take care when interpreting soft tissue injuries identified on MRI.

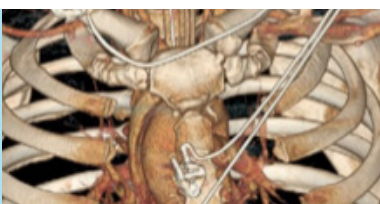
Use MRI to assess patients with neck pain or tenderness out of proportion to the findings on C-spine MDCT to identify potential injuries to ligaments, muscles, or intervertebral disc. A prospective, multicenter observational

study of 767 patients with a negative C-spine MDCT (64 or 128 slice) found that MRI identified additional injuries in 24 percent of patients, and 11 patients required C-spine surgery based on the MRI results.³⁸ Risk factors including neurologic symptoms, midline tenderness, and GCS less than 15 were also found to be strong independent predictors of ligament injury in a single-institution prospective study of 9,227 adult blunt trauma patients.¹³

For an MRI of the C-spine use T2-weighted images to evaluate for cord edema and gradient echo images that are sensitive for detection of hemorrhage. In the subacute and chronic stages after cord trauma, MRI can help define the extent of cord injury. This is particularly important in patients who suffer late deterioration, sometimes caused by treatable etiologies such as development or enlargement of intramedullary cavities.

The Obtunded Patient

The value of a C-spine MRI in the obtunded patient with a negative C-spine MDCT is controversial. *Are the risks associated with performing MRI in obtunded patients worth the possibility of finding the rare case of unstable C-spine injury in a patient with a negative MDCT?* Ligament injuries that are occult on MDCT and identified on MRI rarely result in significant clinical management changes. MRI was found to be positive for soft tissue injury in 6 to 49 percent of patients with an unreliable clinical examination and negative MDCT.^{19,24,26,27,29,39} However, most injuries were minor, requiring either no change in management or only extended cervical collar placement. In fact, less than 1 percent of patients with an unreliable clinical examination



and negative C-spine MDCT have an MRI-identified unstable C-spine injury requiring surgical stabilization.^{19,24,26-29,40}

When comparing MDCT with MRI for clearance of the C-spine in patients being mechanically ventilated, use of MDCT alone resulted in decreased length of intensive care unit (ICU) stay, decreased morbidity related to the rigid cervical collar and ventilation, and no missed unstable C-spine injuries or difference in patient mortality.⁴⁰ MRI has low (64–77 percent) specificity in identifying clinically significant interspinous ligament, intervertebral disc, and paraspinal muscle injury.³⁷

The 2015 Eastern Association for the Surgery of Trauma (EAST) guidelines recommend removal of the cervical collar after a normal C-spine MDCT scan in an unconscious adult patient.⁴¹ The current literature has limitations, and this recommendation is “based on very low quality evidence.” More recent publications indicate that CT misses injuries in a small fraction of patients.^{32,38}

Screening for C-spine injuries in the obtunded patient requires an MDCT. If the MDCT examination shows no injury, the possibility of missing an unstable C-spine injury is very small, but such injuries exist. In the absence of a large multi-center study to determine the costs, risks, and benefits of MRI, it is recommended that a trauma center develop a policy and PI process regarding cervical collar removal and when to perform an MRI in the obtunded patient.

Cervical Spine Imaging in Pediatric Trauma

The overall incidence of C-spine injury in the pediatric population is low (<1 percent).^{42,43} Up to 30 percent of pediatric patients with major TBI have an associated C-spine injury. The injury is most difficult to assess in the 2 to 5 year age group. The risk for a higher anatomical injury is greater the younger the child. Younger children are more likely to suffer ligamentous injury than fracture.

The most utilized references to guide imaging for C-spine clearance are the NEXUS and CCR.⁴⁴ However, both studies included few patients aged less than 5-years, and the number of nonverbal or minimally verbal children was even smaller.⁴⁵ Additionally, both the CCR and the NEXUS criteria are not sensitive or specific enough to be used in children 10-years or younger.^{45,46} In 2009, the AAST published a scoring system for patients aged less than 3-years to determine patients at risk for C-spine injury and possible need for imaging.⁴⁷ The four independent predictors for C-spine injury include:

- GCS < 14
- GCS (Eye criterion) = 1
- Motor vehicle crash (MVC) mechanism of injury
- Age 24–36 months

Imaging is recommended when 3 or 4 criteria are positive.⁴⁷



Recent recommendations for children less than 3 years who do not need pediatric C-spine imaging include those with a GCS greater than 13, no neurologic deficit, no midline tenderness, no distracting injury, no unexplained hypotension, and not intoxicated.⁴⁸ C-spine imaging is also recommended in children less than 3-years-old when the mechanism of injury is a motor vehicle crash (MVC), fall from height greater than 10 feet, or intentional injury.⁴⁸

In the asymptomatic preverbal child, it is acceptable to remove the cervical collar and observe for range of motion and signs of pain. If the range of motion appears normal and no signs of pain are noted, the cervical collar may be left off. If discomfort or decreased range of motion is observed, reapply the collar and pursue radiographic clearance. The asymptomatic child with a reliable clinical examination does *not* require imaging to clear the C-spine.^{48,49} The cervical collar may be removed based on clinical examination of the child alone.

Radiographic Clearance of the Pediatric Cervical Spine

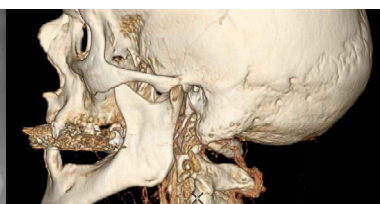
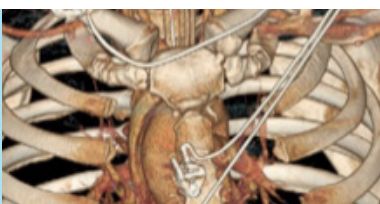
If plain radiographs are obtained, both anteroposterior (AP) and lateral views are required. Flexion and extension views are unnecessary and considered by many to be outdated. Inclusion of the odontoid is difficult to obtain and not necessary.⁴⁹ The sensitivity and specificity of C-spine radiographs is inconsistent in both adult and pediatrics, ranging from 30 to 100 percent, depending on the study referenced.⁵⁰ Difficulties occur because image quality of C-spine

plain radiographs is technician- and patient-dependent. Plain radiographs are often technically difficult to obtain in either the obese or uncooperative pediatric patient. However, the benefit of choosing plain radiographs includes decreased radiation to the thyroid, cornea, and lymphoid tissue.

MDCT for C-spine clearance has 100 percent sensitivity and 95 percent specificity. It has many advantages over radiographs, including ease of application and independence of technician technique. A limited MDCT of C1 to C3 can be performed in conjunction with a head CT or separately when upper C-spine concerns exist. Plain radiographs may then be used to complete evaluation of the C-spine. MDCT imaging is particularly helpful in the infant when adequate radiographs may be difficult to obtain and in the older adolescent when the C-spine approaches skeletal maturity. It is also helpful in patients who have excessive soft tissue of the neck and shoulders that interfere with obtaining an adequate plain radiograph image.

Anatomic variants seen on CT in the pediatric patient include:

- Pseudosubluxation of C2-C3
- Absence of lordosis
- C3 vertebral wedging
- Prevertebral soft tissue thickening
- Pseudo-Jeffersonian fracture



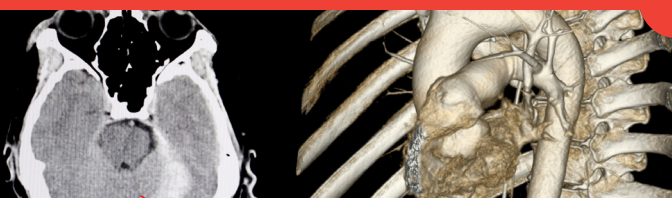MRI is indicated in the neurologically compromised/symptomatic pediatric patient. Disadvantages of its use may include: length of the exam, need for sedation, not available emergently, and “too sensitive” for clinically significant ligamentous injuries.

Special Consideration in Pediatric Patients

- Intubated patients – imaging is required to exclude injury, but it can usually be performed in conjunction with MDCT or MRI brain imaging.
- Intentional injury – the incidence of C-spine injury approaches 15 percent in this special population. Imaging may be important to meet legal documentation needs and to guide medical care. Some trauma centers prefer MRI over MDCT because of its increased sensitivity for identifying ligamentous and soft tissue injury.^{51,52}
- SCIWORA – formerly known as spinal cord injury without radiographic abnormality, it is now more commonly used to describe neurologic deficit in the absence of findings on plain radiographs or MDCT scan. MRI is recommended next, but up to 40 percent of affected patients do not have an injury detected by MRI.⁵³ SCIWORA may be further classified by whether or not abnormalities are detectable. When abnormalities are detected, they are described as “extraneural” or “intraneural”.⁵³ Treatment strategies are not standardized.

References

1. Milby AH, Halpern CH, Guo W, Stein SC. Prevalence of cervical spinal injury in trauma. *Neurosurg Focus*. 2008; 25(5): E10. doi:10.3171/FOC.2008.25.11.E10
2. Hasler RM, Exadaktylos AK, Bouamra O, et al. Epidemiology and predictors of cervical spine injury in adult major trauma patients. *J Trauma Acute Care Surg*. 2012; 72(4): 975-981. doi:10.1097/TA.0b013e31823f5e8e
3. Hoffman JR, Mower WR, Wolfson AB, Todd KH, Zucker MI. Validity of a set of clinical criteria to rule out injury to the cervical spine in patients with blunt trauma. National Emergency X-Radiography Utilization Study Group. *N Engl J Med*. 2000; 343(2): 94-99. doi:10.1056/NEJM200007133430203
4. Stiell IG, Wells GA, Vandemheen KL, et al. The Canadian C-spine rule for radiography in alert and stable trauma patients. *JAMA*. 2001; 286(15): 1841-1848. doi:10.1001/jama.286.15.1841
5. Michaleff ZA, Maher CG, Verhagen AP, Rebeck T, Lin CC. Accuracy of the Canadian C-spine rule and NEXUS to screen for clinically important cervical spine injury in patients following blunt trauma: A systematic review. *CMAJ*. 2012; 184(16): E867-876. doi:10.1503/cmaj.120675
6. Stiell IG, Clement CM, McKnight RD, et al. The Canadian C-spine rule versus the NEXUS low-risk criteria in patients with trauma. *N Engl J Med*. 2003; 349(26): 2510-2518. doi:10.1056/NEJMoa031375
7. Coffey F, Hewitt S, Stiell I, et al. Validation of the Canadian C-spine Rule in the UK emergency department setting. *Emerg Med J*. 2011; 28(10): 873-876. doi:10.1136/emj.2009.089508
8. Griffith B, Kelly M, Vallee P, et al. Screening cervical spine CT in the emergency department, Phase 2: A prospective assessment of use. *AJNR Am J Neuroradiol*. 2013; 34(4): 899-903. doi:10.3174/ajnr.A3306
9. Paxton M, Heal CF, Drobetz H. Adherence to Canadian C-Spine Rule in a regional hospital: a retrospective study of 406 cases. *J Med Imaging Radiat Oncol*. 2012; 56(5): 514-518. doi:10.1111/j.1754-9485.2012.02430.x
10. Duane TM, Young A, Mayglothling J, et al. CT for all or selective approach? Who really needs a cervical spine CT after blunt trauma. *J Trauma Acute Care Surg*. 2013; 74(4): 1098-1101. doi:10.1097/TA.0b013e31827e2acc



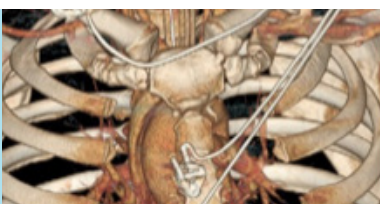
11. Duane TM, Wilson SP, Mayglothling J, et al. Canadian Cervical Spine Rule compared with computed tomography: A prospective analysis. *J Trauma Inj Infect Crit Care*. 2011; 71(2): 352-357. doi:10.1097/TA.0b013e318220a98c
12. Sasser SM, Hunt RC, Faul M, et al. Guidelines for field triage of injured patients: Recommendations of the National Expert Panel on Field Triage, 2011. *MMWR Recommendations and Reports*. 2012; 61(RR01): 1-20. <https://www.cdc.gov/mmwr/preview/mmwrhtml/rr6101a1.htm>. Accessed April 13, 2018.
13. Duane TM, Young AJ, Vanguri P, et al. Defining the cervical spine clearance algorithm: A single-institution prospective study of more than 9,000 patients. *J Trauma Acute Care Surg*. 2016; 81(3): 541-547. doi:10.1097/TA.0000000000001151
14. Healey CD, Spilman SK, King BD, Sherrill JE 2nd, Pelaez CA. Asymptomatic cervical spine fractures: Current guidelines can fail older patients. *J Trauma Acute Care Surg*. 2017; 83(1): 119-125. doi:10.1097/TA.0000000000001497
15. Paykin G, O'Reilly G, Ackland HM, Mitra B. The NEXUS criteria are insufficient to exclude cervical spine fractures in older blunt trauma patients. *Injury*. 2017; 48(5): 1020-1024. doi:10.1016/j.injury.2017.02.013
16. Bailitz J, Starr F, Beecroft M, et al. CT should replace three-view radiographs as the initial screening test in patients at high, moderate, and low risk for blunt cervical spine injury: A prospective comparison. *J Trauma*. 2009; 66(6): 1605-1609. doi:10.1097/TA.0b013e3181a5b0cc
17. Como JJ, Thompson MA, Anderson JS, et al. Is magnetic resonance imaging essential in clearing the cervical spine in obtunded patients with blunt trauma? *J Trauma Acute Care Surg*. 2007; 63(3): 544-549. doi:10.1097/TA.0b013e31812e51ae
18. Diaz JJ, Aulino JM, Collier B, et al. The early work-up for isolated ligamentous injury of the cervical spine: Does computed tomography scan have a role? *J Trauma Acute Care Surg*. 2005; 59(4): 897-904. doi:10.1097/01.ta.0000188012.84356.dc
19. Menaker J, Stein DM, Philp AS, Scalea TM. 40-slice multidetector CT: is MRI still necessary for cervical spine clearance after blunt trauma? *Am Surg*. 2010;76(2):157-163. <http://www.ncbi.nlm.nih.gov/pubmed/20336892>.
20. Awad BI, Carmody MA, Lubelski D, et al. Adjacent level ligamentous injury associated with traumatic cervical spine fractures: Indications for imaging and implications for treatment. *World Neurosurg*. 2015; 84(1): 69-75. doi:10.1016/j.wneu.2015.02.029
21. Tan LA, Kasliwal MK, Traynelis VC. Comparison of CT and MRI findings for cervical spine clearance in obtunded patients without high impact trauma. *Clin Neurol Neurosurg*. 2014; 120: 23-26. doi:10.1016/j.clineuro.2014.02.006
22. Khan SN, Erickson G, Sena MJ, Gupta MC. Use of flexion and extension radiographs of the cervical spine to rule out acute instability in patients with negative computed tomography scans. *J Orthop Trauma*. 2011; 25(1): 51-56. doi:10.1097/BOT.0b013e3181dc54bf
23. Muchow RD, Resnick DK, Abdel MP, Munoz A, Anderson PA. Magnetic resonance imaging (MRI) in the clearance of the cervical spine in blunt trauma: A meta-analysis. *J Trauma Inj Infect Crit Care*. 2008; 64(1): 179-189. doi:10.1097/01.ta.0000238664.74117.ac
24. Menaker J, Philp A, Boswell S, Scalea TM. Computed tomography alone for cervical spine clearance in the unreliable patient? Are we there yet? *J Trauma Inj Infect Crit Care*. 2008; 64(4): 898-904. doi:10.1097/TA.0b013e3181674675
25. Padayachee L, Cooper DJ, Irons S, et al. Cervical spine clearance in unconscious traumatic brain injury patients: Dynamic flexion-extension fluoroscopy versus computed tomography with three-dimensional reconstruction. *J Trauma Inj Infect Crit Care*. 2006; 60(2): 341-345. doi:10.1097/01.ta.0000195716.73126.12
26. Tomycz ND, Chew BG, Chang Y, et al. MRI is unnecessary to clear the cervical spine in obtunded/comatose trauma patients: The four-year experience of a level I trauma center. *J Trauma*. 2008; 64(5): 1258-1263. doi:10.1097/TA.0b013e318166d2bd
27. Schoenfeld AJ, Bono CM, McGuire KJ, Warholc N, Harris MB. Computed tomography alone versus computed tomography and magnetic resonance imaging in the identification of occult injuries to the cervical spine: a meta-analysis. *J Trauma*. 2010; 68(1): 109-13-4. doi:10.1097/TA.0b013e3181c0b67a
28. Panczykowski DM, Tomycz ND, Okonkwo DO. Comparative effectiveness of using computed tomography alone to exclude cervical spine injuries in obtunded or intubated patients: meta-analysis of 14,327 patients with blunt trauma. *J Neurosurg*. 2011; 115(3): 541-549. doi:10.3171/2011.4.JNS101672
29. Plackett TP, Wright F, Baldea AJ, et al. Cervical spine clearance when unable to be cleared clinically: A pooled analysis of combined computed tomography and magnetic resonance imaging. *Am J Surg*. 2016; 211(1): 115-121. doi:10.1016/j.amjsurg.2014.12.041



30. Chew BG, Swartz C, Quigley MR, Altman DT, Daffner RH, Wilberger JE. Cervical spine clearance in the traumatically injured patient: is multidetector CT scanning sufficient alone? Clinical article. *J Neurosurg Spine*. 2013; 19(5): 576-581. doi:10.3171/2013.8.SPINE12925
31. Mavros MN, Kaafarani HMA, Mejaddam AY, et al. Additional imaging in alert trauma patients with cervical spine tenderness and a negative computed tomographic scan: Is it needed? *World J Surg*. 2015; 39(11): 2685-2690. doi:10.1007/s00268-015-3182-6
32. Inaba K, Byerly S, Bush LD, et al; WTA C-Spine Study Group. Cervical spinal clearance: A prospective Western Trauma Association Multi-institutional Trial. *J Trauma Acute Care Surg*. 2016; 81(6): 1122-1130. doi:10.1097/TA.0000000000001194
33. Daffner RH. Helical CT of the cervical spine for trauma patients: A time study. *AJR Am J Roentgenol*. 2001; 177(3): 677-679.
34. Bozzo A, Marcoux J, Radhakrishna M, Pelletier J, Goulet B. The Role of Magnetic Resonance Imaging in the Management of Acute Spinal Cord Injury. *J Neurotrauma*. 2011; 28(8): 1401-1411. doi:10.1089/neu.2009.1236
35. Joaquim AF, Ghizoni E, Tedeschi H, da Cruz HYF, Patel AA. Clinical results of patients with subaxial cervical spine trauma treated according to the SLIC score. *J Spinal Cord Med*. 2014; 37(4): 420-424. doi:10.1179/2045772313Y.00000000143
36. Vaccaro AR, Hulbert RJ, Patel AA, et al; Spine Trauma Study Group. The subaxial cervical spine injury classification system: A novel approach to recognize the importance of morphology, neurology, and integrity of the disco-ligamentous complex. *Spine (Phila Pa 1976)*. 2007; 32(21): 2365-2374. doi:10.1097/BRS.0b013e3181557b92
37. Zhuge W, Ben-Galim P, Hipp JA, Reitman CA. Efficacy of MRI for assessment of spinal trauma: correlation with intraoperative findings. *J Spinal Disord Tech*. 2015; 28(4): 147-151. doi:10.1097/BSD.0b013e31827734bc
38. Maung AA, Johnson DC, Barre K, et al; ReCONNECT MRI C-SPINE Study Group. Cervical spine MRI in patients with negative CT: A prospective, multicenter study of the Research Consortium of New England Centers for Trauma (ReCONNECT). *J Trauma Acute Care Surg*. 2017; 82(2): 263-269. doi:10.1097/TA.0000000000001322
39. Khanna P, Chau C, Dublin A, Kim K, Wisner D. The value of cervical magnetic resonance imaging in the evaluation of the obtunded or comatose patient with cervical trauma, no other abnormal neurological findings, and a normal cervical computed tomography. *J Trauma Acute Care Surg*. 2012; 72(3): 699-702. doi:10.1097/TA.0b013e31822b77f9
40. Stelfox HT, Velmahos GC, Gettings E, Bigatello LM, Schmidt U. Computed tomography for early and safe discontinuation of cervical spine immobilization in obtunded multiply injured patients. *J Trauma Inj Infect Crit Care*. 2007; 63(3): 630-636. doi:10.1097/TA.0b013e318076b537
41. Patel MB, Humble SS, Cullinane DC, et al. Cervical spine collar clearance in the obtunded adult blunt trauma patient: A systematic review and practice management guideline from the Eastern Association for the Surgery of Trauma. *J Trauma Acute Care Surg*. 2015; 78(2): 430-441. doi:10.1097/TA.0000000000000503
42. Rosati SF, Maarouf R, Wolfe L, et al. Implementation of pediatric cervical spine clearance guidelines at a combined trauma center: Twelve-month impact. *J Trauma Acute Care Surg*. 2015; 78(6): 1117-1121. doi:10.1097/TA.0000000000000643
43. Polk-Williams A, Carr BG, Blinman TA, Masiakos PT, Wiebe DJ, Nance ML. Cervical spine injury in young children: A National Trauma Data Bank review. *J Pediatr Surg*. 2008; 43(9): 1718-1721. doi:10.1016/j.jpedsurg.2008.06.002
44. Hoffman JR, Mower WR. National Emergency X-radiography Utilization Study: Doing what's right for your patients. *Emerg Med Australas*. 2005; 17(4): 406-407. doi:10.1111/j.1742-6723.2005.00767.x
45. Ehrlich PF, Wee C, Drongowski R, Rana AR. Canadian C-spine Rule and the National Emergency X-Radiography Utilization Low-Risk Criteria for C-spine radiography in young trauma patients. *J Pediatr Surg*. 2009; 44(5): 987-991. doi:10.1016/j.jpedsurg.2009.01.044
46. Viccellio P, Simon H, Pressman BD, Shah MN, Mower WR, Hoffman JR, for the NEXUS Group. A Prospective multicenter study of cervical spine injury in children. *Pediatrics*. 2001; 108:E20; doi:10.1542/peds.108.2.e2p



47. Piretti-Vanmarcke R, Velmahos GC, Nance ML, et al. Clinical clearance of the cervical spine in blunt trauma patients younger than 3 years: A multi-center study of the American Association for the Surgery of Trauma. *J Trauma*. 2009; 67(3): 543–549.
48. Rozzelle CJ, Aarabi B, Dhall SS, et al. Management of pediatric cervical spine and spinal cord injuries. *Neurosurgery*. 2013; 72(3): 205-226. doi: 10.1227/NEU.0b013e318277096c
49. Chung S, Mikrogianakis A, Wales PW, et al. Trauma Association of Canada Pediatric Subcommittee National Pediatric Cervical Spine Evaluation Pathway: Consensus guidelines. *J Trauma*. 2011; 70(4): 873-884. doi:10.1097/TA.0b013e3182108823
50. Nigrovic LE, Rogers AJ, Adalgais KM, et al; Pediatric Emergency Care Applied Research Network (PECARN) Cervical Spine Study Group. Utility of plain radiographs in detecting traumatic injuries of the cervical spine in children. *Pediatr Emerg Care*. 2012; 28(5): 426-432. doi:10.1097/PEC.0b013e3182531911
51. Governale LS, Brink FW, Pluto CP, et al. A retrospective study of cervical spine MRI findings in children with abusive head trauma. *Pediatr Neurosurg*. 2018; 53(1): 36-42. doi:10.1159/000481511
52. Oh A, Sawvel M, Heaner D, et al. Changes in use of cervical spine magnetic resonance imaging for pediatric patients with nonaccidental trauma. *J Neurosurg Pediatr*. 2017; 20(3): 271-277. doi:10.3171/2017.2.PEDS16644
53. Boese CK, Oppermann J, Siewe J, Eysel P, Scheyerer MJ, Lechler P. Spinal cord injury without radiologic abnormality in children: A systematic review and meta-analysis. *J Trauma Acute Care Surg*. 2015; 78(4): 874-882. doi:10.1097/TA.0000000000000579



4. IMAGING FOR BLUNT CEREBROVASCULAR INJURY

Key Points

- Screening criteria for blunt cerebrovascular injury (BCVI) is based on clinical signs and symptoms, radiologic findings, and high risk or high-energy mechanism of injury.
- Multi-detector CTA, using 64-slice or higher MDCT, is the imaging study of choice for BCVI screening.
- Inclusion of the circle of Willis in imaging studies for BCVI is essential.

Blunt cerebrovascular injury is a relatively rare injury occurring in 0.5 to 3.3 percent of injured patients, depending on the population studied.¹⁻²³ The probability

of sustaining a BCVI is known to increase with a higher injury severity score (ISS).²⁰⁻²¹ BCVI is associated with a high stroke and mortality rate. A high index of suspicion based on the mechanism of injury and injury patterns is critical to detect BCVI. BCVI in children is a diagnosis becoming recognized as awareness increases in pediatric trauma centers. Currently, guidelines for screening pediatric patients are consistent with those for adults.

Screening for Blunt Cerebrovascular Injury

Many different algorithms exist to select blunt trauma patients who need screening for the presence of a BCVI. The criteria proposed by the Denver and Memphis groups are the most widely accepted. These algorithms are based on the presence of clinical and radiological risk factors for BCVI (see Table 5).¹⁻⁹

Table 5. Criteria for BCVI Screening

Criteria Categories	Signs and Findings Present
Clinical signs and symptoms of BCVI	<ul style="list-style-type: none"> • Arterial hemorrhage • Cervical bruit • Expanding cervical hematoma • Focal neurological deficit • Neurologic findings unexplained by intracranial findings • Ischemic stroke on secondary CT scan
Clinical risk factors that mandate radiologic screening for BCVI	<ul style="list-style-type: none"> • High-energy mechanism • Horner's syndrome • Neck soft tissue injury • Near hanging • Direct blow to the neck
Injuries of concern associated with possible BCVI	<ul style="list-style-type: none"> • LeFort II or III fracture • Cervical spine fractures • Basilar skull fracture with or without carotid canal involvement • Diffuse axonal injury



A significant number of patients with BCVI do not meet either the clinical signs and symptoms or clinical risk factors of the screening criteria. Bonatti, et. al. reported that 37.5 percent of the patients diagnosed with a BCVI did not exhibit any of the clinical or risk factors in Table 5.¹¹ However, patients presenting with mechanism of injury risk factors had a significantly higher prevalence of cerebrovascular injuries (8.1 percent) compared with the patients without these risk factors (1.6 percent).¹⁰ With these findings the indication for BCVI screening now includes any blunt trauma patient who sustained a high risk or high-energy mechanism. The three mechanisms of injury from blunt trauma to the cerebrovascular vessels are:

- Severe hyperextension and rotation
- Direct blow to the vessel
- Vessel laceration by adjacent bone fractures

Imaging Study Guidelines

The appropriate imaging study to screen for BCVI has evolved with improvements in imaging technologies. Duplex Doppler ultrasound is not adequate to screen for BCVI. Multi-detector CTA is the current imaging study of choice for BCVI screening. In most instances the images obtained with a 64-slice or higher CT is the only imaging study needed to define the injury. A CTA on a 4-slice scanner is inadequate with unacceptable sensitivity. Treatment is initiated based on the injury grading:¹⁰

- Grade 1 – Intimal irregularity with 25 percent narrowing
- Grade 2 – Dissection or intramural hematoma with 25 percent narrowing
- Grade 3 – Pseudoaneurysm
- Grade 4 – Occlusion
- Grade 5 – Transection with extravasation

Studies by Sliker and by Rademacher demonstrated that a post-contrast acquisition of the neck included into a whole-body MDCT protocol is an acceptable initial means of screening multi-trauma patients for the presence of BCVI.¹⁵⁻¹⁸ This approach is identified as a best practice. Most trauma centers have a CTA protocol that integrates BCVI screening into whole-body CT with a single bolus of contrast, ensuring that the circle of Willis is included.^{11,14,16,22} Some variability exists among trauma centers for specific BCVI imaging, based on whether the circle of Willis is included in the CTA neck or CTA of the brain procedure. Each trauma center needs to develop a protocol to clearly define the correct study for BCVI screening.

Although still considered the gold standard for diagnosis of BCVI, 4-vessel digital subtraction angiography (DSA) has risks of vessel injury, stroke, need for sedation, and specialized personnel to perform. With technology advances, MDCT angiogram is considered the imaging study of choice for BCVI screening.²³ MDCT angiography has been



shown to have a high false positive rate (up to 47.9 percent) especially with Grade I BCVI.²⁴ In this patient population it is recommended to re-evaluate the patient with MDCTA in 7-10 days or proceed with DSA to confirm diagnosis.⁹ DSA is now usually reserved for the patient who requires an endovascular intervention or when a complex lesion needs to be more clearly defined, and when findings on CTA are equivocal or are negative and clinical suspicion remains high.

Magnetic resonance angiography (MRA) requires a longer imaging time and a potential need for sedation that limits its application as a screening study for patients with critical injuries. MRA at the time of MRI of the brain for BCVI screening is judged to be inferior to CTA by the American College of Radiology (ACR), with an assigned appropriateness criteria of 5 (a score of 9 is most appropriate and 1 is least appropriate).

Follow up imaging is needed to reassess the patient diagnosed with BCVI. The timing of follow up imaging remains controversial and varies from 1 week to 3 months, depending of the grade of injury and the clinical condition of the patient.¹⁹⁻²¹

Pediatric BCVI

Screening criteria for pediatric BCVI are based on studies in adult populations and may not be applicable to children.²⁵ Liberal CTA screening in pediatric patients should be avoided due to radiation exposure and a low incidence of this injury. A recent retrospective study of 460 pediatric patients that

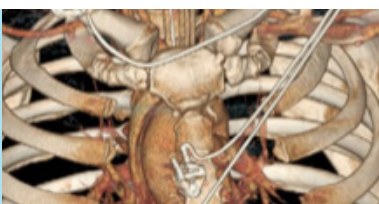
underwent angiography (CT angiography, MR angiography, digital subtraction angiography, and combination of imaging modalities) demonstrated a low incidence of BCVI (0.17 percent, n = 21). The authors noted that the Denver, modified Memphis, EAST and Utah scores did not accurately predict BCVI in children. The authors proposed a new screening tool, the McGovern score, which incorporates mechanism of injury into its screening criteria. The variables included in the McGovern score are GCS \leq 8, focal neurologic deficit, carotid canal fracture, mechanism of injury, petrous temporal bone fracture, and cerebral infarction on CT. The McGovern score was found to have a sensitivity of 81.0 percent, specificity of 71.3 percent, negative predictive value of 98.7 percent for predicting BCVI.²⁶

References

1. Fabian TC, Patton JH, Jr, Croce MA, Minard G, Kudsk KA, Pritchard FE. Blunt carotid injury: Importance of early diagnosis and anticoagulant therapy. *Ann Surg.* 1996; 223(5): 513-522.
2. Biffi WL, Moore EE, Offner PJ, et al. Optimizing screening for blunt cerebrovascular injuries. *Am J Surg.* 1999; 178(6): 517-522.
3. Miller PR, Fabian TC, Bee TK, et al. Blunt cerebrovascular injuries: Diagnosis and treatment. *J Trauma.* 2001; 51(2): 279-285.
4. Biffi WL, Moore EE, Elliott JP, et al. The devastating potential of blunt vertebral arterial injuries. *Ann Surg.* 2000; 231(5): 672-681.
5. Miller PR, Fabian TC, Croce MA, et al. Prospective screening for blunt cerebrovascular injuries: Analysis of diagnostic modalities and outcomes. *Ann Surg.* 2002; 236(3): 386-393.
6. Cothren CC, Moore EE, Ray CE, Jr, et al. Screening for blunt cerebrovascular injuries is cost-effective. *Am J Surg.* 2005; 190(6): 845-849.
7. Ciapetti M, Circelli A, Zagli G et al. Diagnosis of carotid arterial injury in major trauma using a modification of Memphis criteria. *Scand J Traum Resusc Emerg Med.* 2010; 18 (1): 61.



8. Franz RW, Willette PA, Wood MJ, Wright ML, Hartman JF. A systematic review and meta-analysis of diagnostic screening criteria for blunt cerebrovascular injuries. *J Am Coll Surg.* 2012; 214(3): 313–327.
9. Burlew CC, Biffi WL, Moore EE, Barnett CC, Johnson JL, Bensard DD. Blunt cerebrovascular injuries: Redefining screening criteria in the era of noninvasive diagnosis. *J Trauma Acute Care Surg.* 2012; 72(2): 330–335.
10. Biffi WL, Moore EE, Offner PJ, Brega KE, Franciose RJ, Burch JM. Blunt carotid arterial injuries: Implications of a new grading scale. *J Trauma.* 1999; 47(5): 845–853.
11. Bonatti M, Vezzali N, Ferro F et al. Blunt cerebrovascular injury: Diagnosis at whole-body MDCT for multi-trauma. *Insights Imaging.* 2013; 4(3): 347–55.
12. DiCocco JM, Emmett KP, Fabian TC et al. Blunt cerebrovascular injury screening with 32-channel multidetector computed tomography: More slices still don't cut it. *Ann Surg.* 2011; 253 (3): 444–50.
13. Schneiderreit NP, Simons R, Nicolaou S, et al. Utility of screening for blunt vascular neck injuries with computed tomographic angiography. *J Trauma.* 2006; 60(1): 209–215.
14. Fleck SK, Langner S, Baldauf J, Kirsch M, Kohlmann T, Schroeder HW. Incidence of blunt craniocervical artery injuries: Use of whole-body computed tomography trauma imaging with adapted computed tomography angiography. *Neurosurgery.* 2011; 69(3): 615–623.
15. Sliker CW. Blunt cerebrovascular injuries: imaging with multidetector CT angiography. *Radiographics.* 2008; 28(6): 1689–1708.
16. Sliker CW, Shanmuganathan K, Mirvis SE. Diagnosis of blunt cerebrovascular injuries with 16-MDCT: Accuracy of whole-body MDCT compared with neck MDCT angiography. *AJR Am J Roentgenol.* 2008; 190(3): 790–799.
17. Rademacher G, Matthes G, Hosten N, Stengel D. Blunt cerebrovascular injury in patients with blunt multiple trauma: Diagnostic accuracy of duplex Doppler US and early CT angiography. *Radiology.* 2005; 237(3): 884–892.
18. Rademacher G, Mutze S. Gefäßdissektion der hirnversorgenden Arterien: Screening im Rahmen der Ganzkörpercomputertomographie. *Trauma und Berufskrankheit.* 2008; 10:182–186.
19. Stein DM, Boswell S, Sliker CW, Lui FY, Scalea TM. Blunt cerebrovascular injuries: Does treatment always matter? *J Trauma.* 2009; 66(1): 132–143.
20. Bromberg WJ, Collier BC, Diebel LN, et al. Blunt cerebrovascular injury practice management guidelines: The Eastern Association for the Surgery of Trauma. *J Trauma.* 2010; 68(2): 471–477.
21. Biffi WL, Cothren CC, Moore EE, et al. Western Trauma Association critical decisions in trauma: Screening for and treatment of blunt cerebrovascular injuries. *J Trauma.* 2009; 67(6): 1150–1153.
22. Langner S, Fleck S, Kirsch M, Petrik M, Hosten N. Whole-body CT trauma imaging with adapted and optimized CT angiography of the craniocervical vessels: Do we need an extra screening examination? *AJNR Am J Neuroradiol.* 2008; 29(10): 1902–1907.
23. Nagpal BA, Policeni BA, Bathia G, Khandelwal A, Derdyn C, Skeete D. Blunt cerebrovascular injuries: Advances in screening, imaging, and management trends. *Am J Neuroradiol.* 2018; 39(3): 406–414.
24. Grandhi R, Weine GM, Agarwal N, et al. Limitations of multidetector computed tomography angiography for the diagnosis of blunt cerebrovascular injury. *J Neurosurg.* 2018; 128(6): 1642–1647.
25. Ravindra VM, Riva-Cambrin J, Sivakumar W, Metzger RR, Bollo RJ. Risk factors for traumatic blunt cerebrovascular injury diagnosed by computed tomography angiography in the pediatric population: A retrospective cohort study. *J Neurosurg Pediatr.* 2015; 15(6): 599–606.
26. Herbert JP, Venkataraman SS, Turkmani AH, Zhu L, et al. Pediatric blunt cerebrovascular injury: The McGovern screening score. *J Neurosurg Pediatr.* 2018; published online March 16, 2018; doi: 10.3171/2017.12.PEDS17498.



5. CHEST IMAGING

Key Points

- The AP chest radiograph is the single most valuable diagnostic study in the management of chest trauma performed in the trauma receiving area.
- A chest CT is warranted in all adult patients with high-energy torso trauma, a positive chest radiograph, or positive findings on physical examination.
- Chest CT has low sensitivity for detection of blunt cardiac injury.
- For the pediatric patient with minor abnormalities on chest radiograph, chest CT is reported to have no impact on subsequent management.
- A chest CT is recommended for children with an abnormal contour of the mediastinum to an age-appropriate shaped chest.

Chest Radiographs

For the management of chest trauma the AP chest radiograph is the single most valuable diagnostic study performed in the trauma receiving area. The chest radiograph is performed early in the ATLS secondary survey. Every trauma surgeon needs the skill to rapidly interpret the sub-optimal, supine, AP chest radiograph. While digital radiology allows the chest radiograph to be viewed almost instantaneously,

the over-reliance on a quick chest radiograph prior to needed interventions can be life-threatening to the patient.

Because the chest radiograph is taken under adverse conditions in the trauma bay (portable technique, supine position), it has less sensitivity and specificity than the classic standing PA and lateral chest films taken in a dedicated radiology suite. Patients may arrive on backboards that can be either incompatible for radiography or decrease the ability to identify pathology. It is preferable to remove all boards when patients are log-rolled to examine the back. In cases of patients with penetrating trauma, in which no concern about spinal instability exists, consider if it is possible to have the patient sit up to improve the radiograph quality.

Unless gross pathology exists that mandates intervention, download the image to the trauma center's imaging system for higher resolution and post-processing manipulation, rather than viewing the chest radiograph on the digital portable machine. This enhances the ability to diagnose intrathoracic pathology. The radiograph is then read in a consistent and systematic fashion.

- Evaluate first for evidence of pulmonary and pleural pathology, an extension of the "Airway, Breathing and Circulation" phases of the ATLS Primary Survey.
- Note the position of all tubes (endotracheal, thoracostomy), and expansion of the lungs.



- Identify the presence of pneumothorax or hemothorax, which may be obvious or appear as subtle changes in opacity between hemithoraces.
- Note any pulmonary infiltrates suggesting contusions or aspiration, which may explain hypoxemia and help guide management. Infiltrates seen on a screening chest radiograph have correlation with the need for intubation and the development of respiratory failure.¹
- Evaluate an abnormal mediastinum contour, blurring of the aortic knob, apical 'capping' or displacement of the left mainstem bronchus or nasogastric tube. Any of these may suggest an injury of the great vessels in the mediastinum and the potential for hemorrhage.
- Evaluate the diaphragms for evidence of direct injury or elevation due to abdominal pathology.
- Identify any fractures of the ribs, clavicles, scapulae, and humeri.
- Check alignment of the thoracic and upper lumbar vertebrae, recognizing that only the grossest vertebral pathology will be seen.

Fractures provide important clues about the degree of energy transfer to the thorax, and the potential for other, unrecognized injuries. Rib fractures that appear on the initial screening chest radiograph provide clear evidence

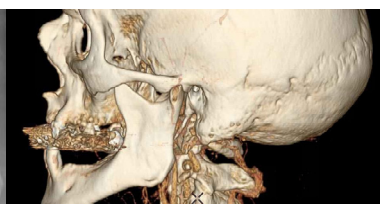
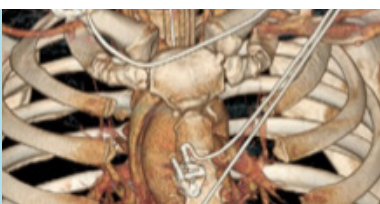
of thoracic and torso trauma, and the number of fractures have been associated with morbidity and mortality.² The presence of any rib fracture increases the likelihood of intraabdominal injuries.³

Pediatric Considerations

The universal use of the plain chest radiography in children, especially younger children with low-grade mechanisms is more open to debate. A single chest radiograph is low risk for radiation exposure. If the patient is to be admitted for observation of other indications in the setting of low risk trauma mechanisms, a chest radiograph may be avoided. However, a chest radiograph is recommended for all patients, regardless of age, in the presence of abnormal physiology, high-grade mechanism of injury, or intubation.

Computed Tomography (CT)

Use of a multi-detector CT scanner is an integral part of the evaluation and treatment of patients sustaining high-energy torso trauma. CT is critical in the management of serious trauma, because it often influences or changes management. Contrast-enhanced chest CT is rated "usually appropriate" by the ACR Appropriateness Criteria in the setting of blunt chest trauma with a high-energy mechanism. In patients with abnormal chest radiographs, altered mental status, distracting injuries, or clinically suspected thoracic injury the ACR Appropriateness Criteria recommend that chest CT be strongly considered.



The NEXUS Chest CT evidence-based decision guideline uses patient history and physical examination to rule-out chest injury in blunt trauma patients and to identify the need for chest CT. It has a 99.9 percent negative predictive value for major chest injury in patients with a normal chest radiograph, and absence of distracting injury, chest wall tenderness, sternum tenderness, thoracic spine tenderness, and scapula tenderness. Sensitivity for major chest injury in the presence of one of these criteria is 99.2 percent.⁴ A contrast-enhanced chest CT is warranted in all adult patients with a high-energy injury mechanism, a positive chest radiograph, or findings on physical examination.

Blunt trauma aortic injury is associated with high mortality, and adequate evaluation of the vessel is critical. Classic “widening” of the mediastinum or abnormal mediastinal contours can suggest aortic injury, but this finding is non-specific. Contrast enhanced MDCT adequately evaluates the aorta and great vessels with reported accuracy of 99.7 percent and NPV of 100 percent.⁵ Talk with the radiologist to determine the need to repeat a contrast-enhanced chest CT performed outside the arterial phase and/or without ECG-gating. In patients with an absolute contraindication to IV-contrast consider a non-contrast chest CT to evaluate for mediastinal hematoma. A low probability of significant aortic injury in the absence of a mediastinal hematoma is reported.

Chest CT identifies additional unsuspected injuries in a majority of major trauma patients who have evidence of chest injury on their initial chest radiograph.⁶ Significant management changes result in up to a third of patients. In patients with a “normal” screening chest radiograph, 15 percent of patients had findings that altered management, further encouraging the liberal use of chest CT. The use of MDCT also provides imaging of the thoracic spine. See the Thoracic and Lumbar Spine Imaging section for more information.

Contrast-enhanced chest CT is also necessary in the diagnosis and treatment of hemodynamically stable patients with suspected transmediastinal gunshot wounds.

Pediatric Considerations

For pediatric patients, use chest CT more selectively to reduce unnecessary imaging. For the child with no, or only minor abnormalities on chest radiograph (for example, simple pneumothorax or hemothorax, pulmonary contusion, or isolated rib fractures), chest CT is reported to have no impact on subsequent management.⁷ A chest CT is recommended for children with an abnormal mediastinal contour to an age-appropriate shaped chest.

Ultrasonography

Ultrasonography, and especially the FAST exam, has become the best practice for rapid diagnosis of traumatic pericardial fluid collections. With increased experience and improved technology, evaluation of the pleural spaces identifying hemothorax



and/or pneumothorax is possible in some trauma centers. Sonographic imaging of the pleural spaces has limitations because sound waves are reflected rather than transmitted by bone and air, making it more operator dependent. However, sonography is inexpensive and typically more rapid than conventional radiology, so its use in chest trauma can be advantageous. At the present time, consider ultrasound of the pleural spaces to be an adjunct, not a replacement for the screening chest radiograph.

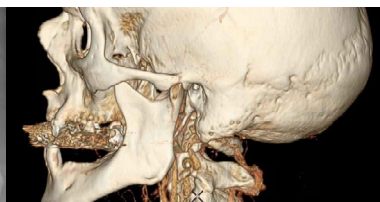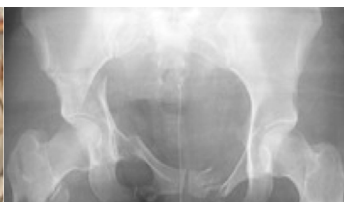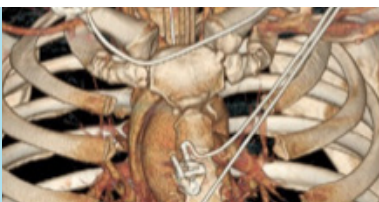
The FAST exam of the heart provides gross information on cardiac function and contractility. While significant blunt cardiac injury is uncommon, it can be the cause of unexplained hypotension, especially when blood loss has been ruled out. Chest CT has low sensitivity for detection of blunt cardiac injury. Perform formal echocardiography for patients suspected to have serious blunt cardiac injury manifested by unexplained hypotension or arrhythmias.

Contrast Studies

Traditional oral contrast studies are rarely obtained in chest trauma patients. They are used most commonly when concern for perforation of the esophagus exists.

References

1. Livingston DH, Shogan B, John P, Lavery RF. CT diagnosis of Rib fractures and the prediction of acute respiratory failure. *J Trauma*. 2008 Apr; 64(4): 905-11.
2. Fligel BT, Luchette FA, Reed RL, et al. Half-a-dozen ribs: The breakpoint for mortality. *Surgery*. 2005 Oct; 138(4): 717-23; discussion 723-5. PubMed PMID: 1629301.
3. Livingston DH, Lavery RF, Passannante MR, et al. Admission or observation is not necessary after a negative abdominal computed tomographic scan in patients with suspected blunt abdominal trauma: Results of a prospective, multi-institutional trial. *J Trauma*. 1998 Feb; 44(2): 273-80; discussion 280-2. PubMed PMID: 9498497.
4. Rodriguez RM, Langdorf MI, Nishijima D, et al. Derivation and validation of two decision instruments for selective chest CT in blunt trauma: A multicenter prospective observational study (NEXUS Chest CT). *PLoS Med*. 2015 Oct 6; 12(10): 1-17. e1001883.
5. Mirvis SE, Shanmuganathan K, Buell J, Rodriguez A. Use of spiral computed tomography for the assessment of blunt trauma patients with potential aortic injury. *J Trauma*. 1998 Nov; 45(5): 922-30.
6. Guerrero-Lopez F, Vazquez-Mata G, Alcazar-Romero PP, Fernandez-Mondejar E, Aguayo-Hoyos E, Linde-Valverde CM. Evaluation of the utility of computed tomography in the initial assessment of the critical care patient with chest trauma. *Crit Care Med*. 2000; 28: 1370-1375.
7. Stephens CQ, Boulos MC, Connelly CR, Gee A, Jafri M, Krishnaswami S. Limiting thoracic CT: A rule for use during initial pediatric trauma evaluation. *J Pediatr Surg*. 2017 Dec; 52(12): 2031-2037. doi: 10.1016/j.jpedsurg.2017.08.039. Epub 2017 Sep 4. PubMed PMID: 28927984.



6. ABDOMINAL IMAGING

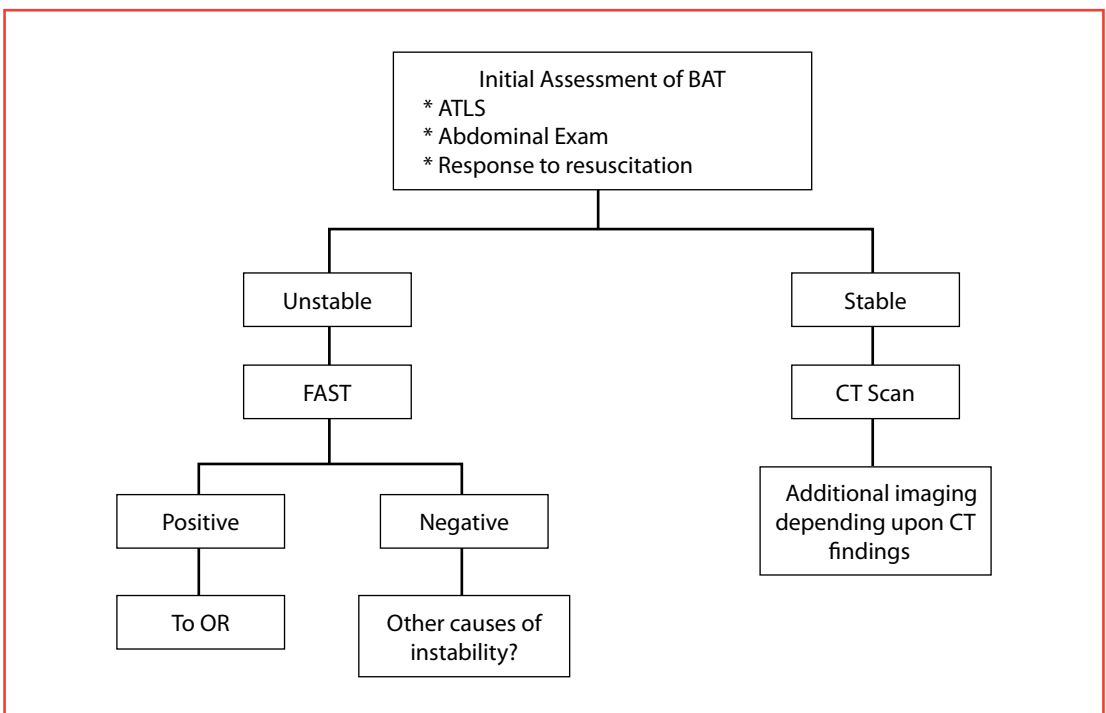
Key Points

- Contrast-enhanced MDCT with multiplanar reformation is the best practice for screening the patient with blunt abdominal trauma.
- FAST has acceptable sensitivity (69–98 percent) for detection of free fluid and lower sensitivity (63 percent) for detection of solid organ injury in adults.
- A negative FAST does not rule out intraabdominal injury.
- An existing indication for laparotomy is the only absolute contraindication for radiographic assessment of the abdomen.

- Criteria for predicting children at very low risk for intraabdominal injury exist to determine the necessity of abdominal CT.

Evaluation of the abdomen is an important component in the initial assessment of the injured patient. Unrecognized abdominal injury continues to be a cause of preventable death after trauma to the torso. The mechanism of injury, hemodynamic status, and physical examination are the most important determinants of the radiologic assessment. An existing indication for laparotomy is the only absolute contraindication for radiographic assessment of the abdomen. See Figure 4 for the initial evaluation of a patient with blunt abdominal trauma.

Figure 4. Initial Assessment of Blunt Abdominal Trauma (BAT)



Courtesy of Christine Cocanour, MD, FACS



Focused Assessment Sonography in Trauma (FAST)

The FAST exam is a tool for the rapid assessment of a trauma patient.

FAST includes four views:

- Pericardial view,
- Right upper quadrant view to include the diaphragm-liver interface and Morrison's pouch,
- Left upper quadrant view to include diaphragm-spleen interface and spleen-kidney interface, and
- Suprapubic view.

When the patient is hemodynamically unstable, FAST is performed for detection of intraabdominal free fluid suggestive of hemoperitoneum. A positive FAST in this context allows quick triage to the operating room for exploratory laparotomy. FAST has acceptable sensitivity (69–98 percent) for detection of free fluid and lower sensitivity (63 percent) for detection of solid organ injury.¹⁻³ Obtaining serial FAST examinations increases overall sensitivity (72–93 percent).⁴⁻⁶ Because FAST has high specificity, an unstable trauma patient with a positive FAST goes to the OR. In a stable patient, FAST has limited sensitivity for detecting the presence of an injury that might require intervention, and not all injuries detectable by FAST require intervention.⁷⁻¹⁰

FAST in the Pediatric Patient

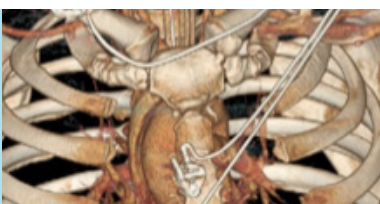
It was hoped that FAST would be a useful and cost-effective tool to evaluate blunt abdominal trauma in children to avoid radiation exposure. A recent, prospective, single-center study reported the use of FAST in hemodynamically stable pediatric patients with blunt torso trauma. Study findings do not support the use of FAST in the pediatric patient.¹¹ The sensitivity and specificity of FAST are less in children than in adults. The use of FAST in children is only recommended if the child is in shock or when CT is not available or not feasible.

Ultrasound

Contrast-enhanced ultrasound is more sensitive and accurate than ultrasound, and it is nearly as sensitive as CT in the identification and characterization of solid organ lesions in blunt abdominal trauma. CT, however, is more sensitive and accurate than contrast-enhanced ultrasound in identifying active bleeding and urinary tract injuries.¹² While a role for this technique is emerging, it is not at the level of best practice.

Computed Tomography

MDCT with multiplanar reformations is the best practice for screening the patient with blunt abdominal trauma. It accurately identifies active hemorrhage, as well as hepatobiliary, splenic, pancreatic, and genitourinary injury. Bowel and diaphragmatic injury are more challenging to diagnose.^{13,14} Newer generation CT scanners provide improved accuracy of intestinal injury identification, however, this remains an injury that is sometimes missed. Newer



generation scanners with multiplanar reformation may decrease the risk of missing diaphragmatic injury.¹⁵ In pediatric patients, MDCT is less accurate than in adults for the diagnosis of diaphragmatic injury. Studies report it is safe to discharge patients home in the absence of clinical peritonitis and a negative abdominal MDCT.¹⁶

Obtain an abdominopelvic CT with low osmolar IV contrast. Oral contrast is not indicated in either adult or pediatric blunt trauma patients. Bleeding is critical to detect on CT and often requires imaging at two points of time to help identify and distinguish active arterial hemorrhage from pseudoaneurysm. The portal venous phase is optimal for evaluation of visceral parenchymal injury. Delayed excretory phase images are also essential for evaluation of the renal collecting system and bladder injuries. These images may be obtained at 4-5 minutes or up to an hour after IV contrast injection.

AAST grading is recommended for radiologic reporting of injuries, however, the current system is variable in its ability to predict the need for intervention or patient outcomes.

Pediatric Blunt Abdominal Trauma Imaging Algorithms

Minimizing unnecessary imaging in pediatric patients is an important principle. For blunt abdominal trauma in children, two recent multicenter studies defined criteria for predicting children at very low risk for intraabdominal injury. The PECARN used history and

physical examination alone to identify children at very low risk of intraabdominal injury requiring acute interventions.¹⁷ Additionally, Streck et al. used clinical data readily available in the trauma bay to identify children at very low risk for intraabdominal injury and for whom a CT scan is not necessary. This prediction rule in descending order of significance includes:¹⁸

- Aspartate aminotransferase >200 U/L,
- Abnormal abdominal examination,
- Abnormal chest radiograph, report of abdominal pain, and
- Abnormal pancreatic enzymes.

The Streck *et al.* rule had a negative predictive value of 99.4 percent for intraabdominal injury and 100 percent for patients with intraabdominal injury that required acute interventions.¹⁸ Familiarity with these algorithms is important to guide identification of children less likely to need abdominal imaging. Further validation of these prediction rules is ongoing.

Further Diagnostic Work-Up of Specific Injuries Identified on CT

Adrenal Injury

The best diagnostic tool for adrenal gland injury is the abdominal MDCT scan. Typical CT findings of adrenal injury are round or oval hematomas expanding the adrenal gland, irregular hemorrhage obliterating the gland, and uniform adrenal gland swelling with indistinct margins.¹⁹



Duodenal Injury

Duodenal perforation produces subtle but typical findings on MDCT, such as extraluminal air or fluid in the retroperitoneum or periportal region. Surgical exploration is generally mandated. The presence of duodenal hematoma does not mandate exploration, but it does require close observation.

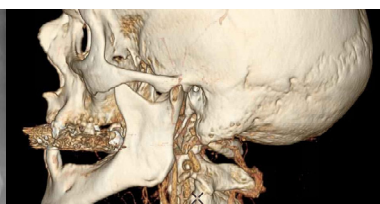
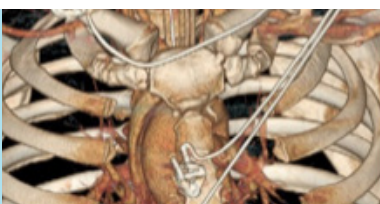
Bowel Injury

With the evolution of CT scanners most significant traumatic bowel and mesenteric injuries can be identified in both children and adults. The classic presence of a moderate amount of free intraabdominal fluid without solid organ injury is suggestive of bowel injury. Small amounts of free fluid may be a result of resuscitation. More subtle signs of bowel injury on CT include bowel-wall thickening, mesenteric stranding, and bowel-wall enhancement. The combination of bowel-wall thickening and free fluid cannot distinguish between a major bowel injury (i.e., bowel perforation) and minor bowel injury (i.e., serosal tears). Mesenteric stranding can be associated with mesenteric injury with or without bowel perforation, but bowel-wall thickening associated with stranding is highly suggestive of significant bowel injury. Although intraabdominal fluid may be present from solid organ injury, the presence of interloop fluid between the folds of mesentery and bowel are more likely to be related to bowel or mesenteric injury.

When suspicion of bowel injury exists, options include laparoscopy, open exploration, or a period of observation with repeat CT scan. For pediatric patients repeat CT scan is not advocated, and more reliance is placed on the abdominal examination. Either laparoscopic or open exploration is performed if the examination findings worsen.²⁰

Pancreatic Injury

Signs of pancreatic injury on MDCT include laceration, transection, bulky pancreas, heterogeneous enhancement, peri-pancreatic fluid, and signs of pancreatitis. Evidence of pancreatic injury on CT imaging may not be noted in the first 12 to 24 hours after injury. Lacerations involving more than half of the pancreatic parenchymal depth are suggestive of ductal injury. If ductal laceration is seen or a high suspicion exists for pancreatic duct injury, exploration is indicated. If the CT is inconclusive, consider a repeat CT at 6-24 hours (for pediatric patients, a repeat CT is not recommended). If continued concern exists about a potential ductal disruption, a magnetic resonance cholangiopancreatography (MRCP) or ERCP can directly assess the pancreatic duct to guide surgical management.



References

1. Richards JR, McGahan JP. Focused Assessment with Sonography in Trauma (FAST) in 2017: What Radiologists Can Learn. *Radiology*. 2017 Apr; 283(1): 30-48.
2. Pearl WS, Todd KH. Ultrasonography for the initial evaluation of blunt abdominal trauma: A review of prospective trials. *Ann Emerg Med*. 1996; 27(3): 353-361.
3. McGahan JP, Rose J, Coates TL, Wisner DH, Newberry P. Use of ultrasonography in the patient with acute abdominal trauma. *J Ultrasound Med*. 1997; 16(10): 653-662.
4. Nunes LW, Simmons S, Hallowell MJ, Kinback R, Trooskin S, Kozar R. Diagnostic performance of trauma US in identifying abdominal or pelvic free fluid and serious abdominal or pelvic injury. *Acad Radiol*. 2001; 8(2): 128-136.
5. Blackburne LH, Soffer D, McKenney M, et al. Secondary ultrasound examination increases the sensitivity of the FAST exam in blunt trauma. *J Trauma*. 2004 Nov; 57(5): 934-8.72.
6. Rajabzadeh Kanafi A, Giti M, Gharavi MH, Alizadeh A, Pourghorban R, Shekarchi B. Diagnostic accuracy of secondary ultrasound exam in blunt abdominal trauma. *Iran J Radiol*. 2014 Aug; 11(3): e21010.
7. Shanmuganathan K, Mirvis SE, Sherbourne CD, Chiu WC, Rodriguez A. Hemoperitoneum as the sole indicator of abdominal visceral injuries: A potential limitation of screening abdominal US for trauma. *Radiology*. 1999 212(2): 423-430.
8. Miller MT, Pasquale MD, Bromberg WJ, Wasser TE, Cox J. Not so FAST. *J Trauma*. 2003; 54(1): 52-59; discussion 59-60.
9. Carter JW, Falco MH, Chopko MS, Flynn WJ Jr, Wiles lli CE, Guo WA. Do we really rely on fast for decision-making in the management of blunt abdominal trauma? *Injury*. 2015; 46(5): 817-821.
10. Chiu WC, Cushing BM, Rodriguez A, et al. Abdominal injuries without hemoperitoneum: A potential limitation of focused abdominal sonography for trauma (FAST). *J Trauma*. 1997; 42(4): 617-623; Discussion 623-625.
11. Holmes JF, Kelley KM, Wootton-Gorges SL, et al. Effect of abdominal ultrasound on clinical care, outcomes, and resource use among children with blunt torso trauma: A randomized clinical trial. *JAMA*. 2017 Jun; 13; 317(22): 2290-2296.
12. Menichini G, Sessa B, Trinci M, Galluzzo M, Miele V. Accuracy of contrast-enhanced ultrasound (CEUS) in the identification and characterization of traumatic solid organ lesions in children: A retrospective comparison with baseline US and CE-MDCT. *Radiol Med*. 2015 Nov; 120(11): 989-1001.
13. Landry BA, Patias MN, Faidi S, Coates A, Nicolaou S. Are we missing traumatic bowel and mesenteric injuries *Can Assoc Radiol J*. 2016 Nov; 67(4): 420-425. doi: 10.1016/j.carj.2015.11.006.
14. Leung VA, Patias MN, Reid S, Coates A, Nicolaou S. Imaging of traumatic diaphragmatic rupture: Evaluation of diagnostic accuracy at a Level 1 trauma center. *Can Assoc Radiol J*. 2015 Nov; 66(4): 310-7. doi: 10.1016/j.carj.2015.02.001.
15. Patlas MN, Leung VA, Romano L, Gagliardi N, Ponticello G, Scaglione M. Diaphragmatic injuries: Why do we struggle to detect them? *Radiol Med*. 2015 Jan; 120(1): 12-20.
16. Livingston DH, Lavery RF, Passannante MR, et al. Admission or observation is not necessary after a negative abdominal computed tomographic scan in patients with suspected blunt abdominal trauma: Results of a prospective, multi-institutional trial. *J Trauma*. 1998 Feb; 44(2): 273-80; discussion 280-2.
17. Holmes JF, Lillis K, Monroe D, et al; Pediatric Emergency Care Applied Research Network (PECARN). Identifying children at very low risk of clinically important blunt abdominal injuries. *Ann Emerg Med*. 2013 Aug; 62(2): 107-116.e2.
18. Streck CJ, Vogel AM, Zhang J; Pediatric Surgery Research Collaborative. Identifying children at very low risk for blunt intra-abdominal injury in whom CT of the abdomen can be avoided safely. *J Am Coll Surg* 2017 Apr; 224(4):449-458. e3.
19. Pinto A, Scaglione M, Pinto F, Gagliardi N, Romano L. Adrenal injuries: Spectrum of CT findings. *Emerg Radiol*. 2003 Apr; 10(1): 30-3.
20. Chatoorgoon K, Brown RL, Garcia VF, Falcone RA Jr. Role of computed tomography and clinical findings in pediatric blunt intestinal injury: A multicenter study. *Pediatr Emerg Care*. 2012; 28(12): 1338-42.



7. GENITOURINARY IMAGING

Key Points

- Indications for urinary system imaging of adults and pediatric patients after blunt trauma include gross hematuria or the combination of microscopic hematuria and hemodynamic instability.
- Delayed, excretory phase imaging is necessary to exclude collecting system injury (beginning at 4 to 5 minutes post-injection for up to one hour following IV contrast injection).
- Use a defined protocol for CT cystography that is unique for adults and children, to adequately fill and evaluate the bladder.
- Obtain a retrograde urethrogram in males when urethral injury is suspected by placing a Foley catheter or catheter-tipped syringe into the fossa navicularis.

Renal Injury

Adult patients who require urologic imaging after blunt trauma include those with gross hematuria or the combination of microscopic hematuria (greater than 5 red blood cells per high-power field) and hemodynamic instability (SBP less than 90 mmHg).^{1,2} Additional indications suggestive of renal injury include a rapid deceleration injury mechanism, a significant blow to the flank, rib fracture, or flank ecchymosis. The absence of hematuria does not exclude GU injury. Patients sustaining

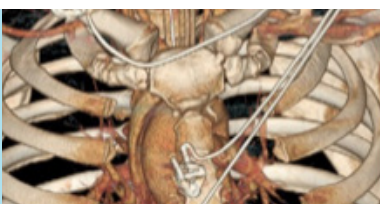
penetrating trauma to the abdomen, flank or lower chest) with trajectory in proximity to the kidneys based on entry/exit sites need urologic imaging.

CT with IV contrast in a portal venous phase that includes delayed excretory phase images allows evaluation of the collecting system and parenchymal injuries. These images to evaluate the urinary tract may be obtained at 4-5 minutes and up to an hour following the IV contrast injection.³ If vascular injuries are suspected, include arterial phase images. Selected delayed phase images can be obtained when evidence of renal or ureteral trauma is seen on initial imaging.

An intraoperative, single shot IVP may be used to confirm a contralateral functioning kidney if the patient is taken directly to the operating room without obtaining a CT and the patient is found to require a nephrectomy.⁴ Consider use of an IVP in emergent situations if CT imaging is not available. If GU tract injury is suspected and CT is not available, consider transfer to a higher level of care.

Pediatric Considerations

Like adult patients, either gross hematuria or hypotension with microscopic hematuria mandate abdominal/pelvic CT regardless of the mechanism. Although factors such as injury mechanism, and physical exam findings may influence the decision to perform CT imaging, microscopic hematuria alone is generally not an indication for CT imaging of the abdomen and pelvis in pediatrics.⁵



Ureteral Injury

Ureteral injuries constitute less than 1 percent of all urinary tract injuries. Neither CT nor IVP is totally reliable in detecting ureteral injuries. Delayed excretory phase images obtained at 4-5 minutes after contrast infusion increases the sensitivity in detecting ureter disruption.²

Bladder Injury

A patient with gross hematuria and a pelvic fracture (especially involving the anterior pelvic ring or pubic rami) requires evaluation of the bladder with CT or plain film retrograde cystography. Consider cystography for the following indications: gross hematuria, an injury mechanism with potential for bladder injury, pelvic ring fractures, inability to void, low urine output, increased BUN and creatinine, abdominal distention, suprapubic pain, or urinary ascites.

In performing a CT cystogram, clamping the Foley catheter to allow bladder filling after an abdomen and pelvis CT does not provide adequate bladder distention or pressure for bladder injury evaluation. To perform a CT cystogram, use a defined protocol, unique for adults and children, to adequately fill the bladder in a retrograde fashion. Post void images are not necessary for CT. If performing the cystogram using radiographic films, obtain images at maximum fill and again after bladder drainage. Consider obtaining additional oblique views.

Urethral Injury

Obtain a retrograde urethrogram when urethral injury is suspected by findings that include: blood at the urethral meatus, a ballotable prostate, pain with voiding or inability to void, perineal or penile hematoma, or a straddle mechanism of injury. The retrograde urethrogram is performed by placing a Foley catheter or catheter-tipped syringe into the fossa navicularis. A pericatheter retrograde urethrogram can be obtained if a Foley catheter is in situ.

Penile Fracture

When penile fracture is suspected, ultrasound is the imaging study of choice, if the diagnosis cannot be made on physical exam.⁶ MRI imaging of the penis provides excellent delineation of anatomy, however, reserve it for occasions when injury appears absent on other studies and the patient would benefit from nonoperative management. Because concomitant urethral injury must be considered, also obtain a retrograde urethrogram.

Scrotal Injury

Consider additional imaging of the scrotum with findings on physical exam that include the presence of scrotal ecchymosis, swelling, or ill-defined testicular contours. Use ultrasound to further evaluate potential injury.

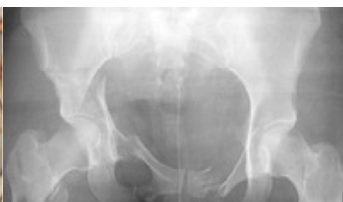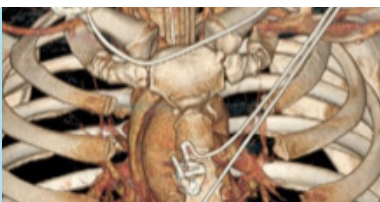
Female Genitalia Injury

Suspect female genital injury based on history or blood at the vaginal introitus. Further diagnostic workup can include ultrasound, CT, or MRI.



References

1. Mee SL, McAninch JW, Robinson AL, Auerbach PS, Carroll PR. Radiographic assessment of renal trauma: A 10-year prospective study of patient selection. *J Urol.* 1989; 141: 1095-8.
2. Brown SL, Hoffman DM, Spirnak JP. Limitations of routine spiral computerized tomography in the evaluation of blunt renal trauma. *J Urol.* 1998; 160: 1979-81.
3. Morey AF, Brandes S, Dugi DD 3rd, et al. American Urological Association. Urotrauma: AUA guideline. *J Urol.* 2014; 192(2): 327-335,
4. Nagy KK, Brenneman FD, Krosner SM, et al. Routine preoperative "one shot" intravenous pyelography is not indicated in all patients with penetrating abdominal trauma. *J Am Coll Surg.* 1997; 185: 530-533.
5. Perez-Brayfield MR, Gatti JM, Smith EA, et al. Blunt traumatic hematuria in children. Is a simplified algorithm justified? *J Urol.* 2002; 167(6): 2543-2546.
6. Kachewar S, Kulkarni D. Ultrasound evaluation of penile fractures. *Biomed Imaging Interv J.* 2011 Oct; 7(4): e27. doi: 10.2349/bij.7.4.e27.



8. THORACIC AND LUMBAR SPINE IMAGING

Key Points

- No widely used and validated criteria exist to guide the appropriate use of thoracolumbar spine imaging.
- Maintain a low threshold for imaging the thoracolumbar spine in patients with blunt trauma as clinical exam has a low sensitivity for identifying injuries.
- Signs of spinal cord, conus medullaris, or nerve root injury are indications to obtain an MRI of the symptomatic levels of the spine and spinal cord.
- Patients with cervical spine injury should have imaging of the entire spine.

Injuries to the thoracolumbar spine are more prevalent than C-spine injury. An estimated 4 to 7 percent of patients presenting to the ED with blunt trauma have a fracture of the thoracolumbar spine.^{1,2} Paradoxically, an increased rate of thoracolumbar spine fractures occurred in the United States over the past several decades, despite a decline in other motor vehicle-related injuries.³ This increase in thoracolumbar injury is potentially related to a higher detection rate and an increased rate of injuries associated with greater seatbelt use. A wide spectrum of thoracolumbar spine injuries occur, ranging from stable minor soft tissue injuries to unstable fracture-dislocations that are often accompanied by neurologic injuries.

Imaging Decision Making

In contrast to the C-spine, no widely used and validated criteria exist to guide decision making about imaging the thoracolumbar spine.⁴⁻⁶ Clinical exam has a low to very low sensitivity for identifying thoracolumbar spine injuries.^{2,7,8} Maintain a low threshold for screening the thoracolumbar spine with imaging in the setting of blunt trauma in patients with complaints of thoracolumbar pain, thoracolumbar spine tenderness, abnormal neurologic examination, high risk mechanism, and distracting injury. This is particularly true of older patients at high risk for thoracolumbar fractures.

Fractures found at one level of the spine are often associated with injury at other, noncontiguous levels of the C-spine. Therefore, screen the entire spine whenever an injury of the spine is identified.

Computed Tomography

When imaging is necessary, use MDCT scans with sagittal and coronal reformatted images to screen for thoracic and lumbar spine fractures.⁹ However, the sensitivities of detecting a thoracic or lumbar spine fracture using 5mm slice CT scan is 85.7 percent.¹⁰ Use high-quality thin section images to generate multiplanar reformations in transaxial, sagittal, and coronal planes. Sensitivity approaches 100 percent for thoracolumbar spine CT no thicker than 3mm with multiplanar reformations.¹⁰



The ACR Practice Guideline for the Performance of Computed Tomography of the Spine suggests that the CT slice thickness be no greater than 5mm for evaluation of the thoracolumbar spine.¹¹ Herzog *et al.* imaged 70 blunt polytrauma patients with conventional radiographs, 5mm slice CT scan, 3mm slice CT scan, and then 5mm and 3mm slices with multiplanar reconstruction. The respective sensitivities for thoracic fractures were 57.1 percent, 85.7 percent, 100 percent, 95.2 percent, and 100 percent. For lumbar spine fractures, the sensitivities were 57.1 percent, 85.7 percent, 85.7 percent, 100 percent, and 100 percent.¹⁰

When to Perform MRI

Isolated unstable ligamentous injury in the absence of fractures is rare in the thoracolumbar spine. Screening the thoracolumbar spine with MRI for detecting ligamentous disruption is not indicated when the CT scan is normal. However, symptoms or signs of spinal cord, conus medularis, or nerve root injury indicate the need for imaging the thoracolumbar spine and spinal cord with MRI.

MRI is a valuable tool for assessing patients with known or possible unstable vertebral injury. In addition to assessing the fractures, MRI aids evaluation of ligament integrity to determine spinal stability. It also contributes to imaging the spinal cord for transection, contusion, edema, or hematoma. Cord

compression by bone fragments, disc herniation, and epidural or subdural hematomas can also be demonstrated.

Consider MRI in consultation with the spine surgeon for MDCT findings suggestive of neurologic involvement and of gross neurologic deficits.⁹ Include both T2-weighted images and gradient echo images in the MRI examination of the thoracic or lumbar portions of the spine. In the subacute and chronic stages after cord trauma, MRI can help define the extent of cord injury. This is particularly important in patients who suffer late deterioration, sometimes caused by treatable etiologies such as development or enlargement of intramedullary cavities.

Pediatric Imaging of the Thoracic and Lumbar Spine

Routine imaging is generally not based on injury mechanism alone. AP and lateral radiographs are indicated for physical examination findings or symptoms. Obesity may affect the quality of radiographs.

Thoracic and lumbar spine CT may be performed for the pediatric patient with normal radiographs who is neurologically intact but has pain. If a patient had a CT of the chest, abdomen, and pelvis, reconstructed views obviate the need for further CT. Neurologically compromised patients generally require an MRI for evaluation of the spine.⁷



References

1. Cooper C, Dunham CM, Rodriguez A. Falls and major injuries are risk factors for thoracolumbar fractures: Cognitive impairment and multiple injuries impeded the detection of back pain and tenderness. *J Trauma*. 1995; 38(5): 692-696.
2. Katsuura Y, Osborn JM, Cason GW. The epidemiology of thoracolumbar trauma: A meta-analysis. *J Orthop*. 2016; 13(4): 383-388. doi:10.1016/j.jor.2016.06.019
3. Doud AN, Weaver AA, Talton JW, et al. Has the incidence of thoracolumbar spine injuries increased in the United States from 1998 to 2011? *Clin Orthop Relat Res*. 2015; 473(1): 297-304. doi:10.1007/s11999-014-3870-9
4. Hsu JM, Joseph T, Ellis AM. Thoracolumbar fracture in blunt trauma patients: Guidelines for diagnosis and imaging. *Injury*. 2003; 34(6): 426-433. doi:10.1016/S0020-1383(02)00368-6
5. Holmes JF, Panacek EA, Miller PQ, Lapidis AD, Mower WR. Prospective evaluation of criteria for obtaining thoracolumbar radiographs in trauma patients. *J Emerg Med*. 2003; 24(1): 1-7. doi:10.1016/S0736-4679(02)00659-5
6. Inaba K, Nosanov L, Menaker J, et al; AAST TL-Spine Multicenter Study Group. Prospective derivation of a clinical decision rule for thoracolumbar spine evaluation after blunt trauma: An American Association for the Surgery of Trauma Multi-Institutional Trials Group Study. *J Trauma Acute Care Surg*. 2015; 78(3): 459-467. doi:10.1097/TA.0000000000000560
7. Inaba K, DuBose JJ, Barmparas G, et al. Clinical examination is insufficient to rule out thoracolumbar spine injuries. *J Trauma Inj Infect Crit Care*. 2011; 70(1): 174-179. doi:10.1097/TA.0b013e3181d3cc6e
8. Venkatesan M, Fong A, Sell PJ. CT scanning reduces the risk of missing a fracture of the thoracolumbar spine. *Bone Joint J*. 2012; 94-B(8): 1097-1100. doi:10.1302/0301-620X.94B8.29397
9. Sixta S, Moore FO, Ditillo MF, et al. Screening for thoracolumbar spinal injuries in blunt trauma: An Eastern Association for the Surgery of Trauma practice management guideline. *J Trauma Acute Care Surg*. 2012; 73(5 Suppl 4): S326-32. doi:10.1097/TA.0b013e31827559b8
10. Herzog C, Ahle H, Mack MG, et al. Traumatic injuries of the pelvis and thoracic and lumbar spine: Does thin-slice multidetector-row CT increase diagnostic accuracy. *Eur Radiol*. 2004; 14(10): 1751-1760. doi:10.1007/s00330-004-2424-z
11. ACR-ASNR-ASSR-SPR. Practice Parameters For the Performance of Computed Tomography (CT) Of The Spine. 2016. <https://www.acr.org/-/media/ACR/Files/Practice-Parameters/ct-spine.pdf?la=en>. Accessed April 15, 2018.



9. WHOLE-BODY CT IMAGING

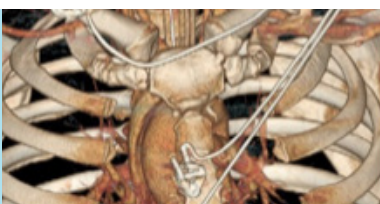
Key Points

- Multi-detector computed tomography (MDCT) allows immediate imaging of multiple body regions and accurately identifies injuries that may not be evident on initial physical examination.
- Whole-body CT (WBCT) generally involves non-contrast imaging of the head and C-spine followed by contrast-enhanced imaging of the chest, abdomen, and pelvis.
- Identification of clinically unsuspected or occult injuries using WBCT frequently results in management changes, and a negative study may allow earlier discharge from the ED.
- WBCT has not been widely adopted for pediatric patients due to concerns about the long-term impact of ionizing radiation.

Whole-Body CT in Adults

Blunt trauma patients frequently sustain multi-system injuries requiring rapid and accurate diagnosis to establish treatment priorities. MDCT allows immediate imaging of multiple body regions and accurately identifies injuries that may not be evident on initial physical examination. For this reason, trauma centers increasingly integrate a whole-body or pan-CT into the initial evaluation of major trauma patients.

WBCT includes head through pelvis complete CT imaging. This may be *single pass* (CT head, then CTA neck through pelvis, then venous phase abdomen and pelvis), or *dual pass* (CT head, face C-spine, then enhanced chest, abdomen and pelvis after arms elevated). WBCT generally involves non-contrast imaging of the head and C-spine followed by contrast-enhanced imaging of the chest, abdomen and pelvis with thoracolumbar spine reformations (two-dimensional representations of CT data, e.g. sagittal and coronal). The exact technique used varies between trauma centers because uniform consensus does not exist, and technique will in part depend on the trauma center's volume and patient injury (e.g. high-energy vs. low energy, percent blunt vs. penetrating injury). Some trauma centers use single phase imaging for the entire run. Other trauma centers use arterial-phase imaging of the chest, abdomen and pelvis followed by venous-phase imaging of the abdomen and pelvis. Some centers now advocate a single-pass arterial-phase imaging from the Circle of Willis, including cervical spine (to screen for blunt cerebrovascular injuries), through the pelvis followed by venous-phase imaging of the abdomen and pelvis, without increasing the radiation dose or contrast load delivered.^{1,2} The alternative to WBCT is "selective regional CT" imaging guided by history, physical examination, and non-CT imaging.



While WBCT is widely utilized, a lack of consensus exists about indications for its use.³ Physical examination findings that suggest multi-system injury in a hemodynamically stable patient generally warrant WBCT. Another indication is altered level of consciousness after major trauma, which makes the physical examination unreliable and is predictive of multi-region injury.³ Physical examination may be unreliable even in awake patients,^{4,5} and with significant mechanism of injury, WBCT may be appropriate.

Potential benefits of early WBCT in the evaluation of blunt trauma patients include: identification of clinically unsuspected injuries resulting in management changes, reduction in time to diagnosis and treatment, earlier discharge of patients with negative CTs, and avoidance of repeat contrast loads with sequential CTs.⁶ The benefits of liberal scanning must be weighed against concerns for increased radiation exposure and cost.

In a retrospective study, routine thoracic, abdominal and pelvic CT in patients with closed head injury demonstrated unexpected findings in 38 percent of patients, leading to treatment changes in 26 percent, and 4.3 percent of patients underwent immediate operation because of CT findings.⁷ In a prospective study of WBCT in 1000 consecutive patients following blunt multi-system trauma, 19 percent of patients had treatment altered, either because of abnormal CT findings or because of a normal scan. Treatment changes included prompt hospital discharge or release

to other services, admission for serial examination, further evaluation of injuries and immediate operative intervention. Even in the 592 patients without obvious external signs of injury, abnormalities were found in 35 percent of the head CT scans, 5.1 percent of cervical spine CT scans, 19.6 percent of chest CT scans, and 7.1 percent of abdominal CT scans.⁵

WBCT allows some trauma patients to be safely discharged after significant mechanisms of injury, avoiding a period of observation in the hospital.^{8,9} It also allows rapid clearance of patients who require prompt operative intervention (e.g. open fractures, craniotomy, spine procedures) who might otherwise require serial physical examination before going to the operating room.

Rapid diagnosis and treatment remains the cornerstone of trauma management. Both stable patients and those who respond to initial resuscitation are able to undergo complete imaging with WBCT in under 20 minutes. Several studies have demonstrated the time management advantages of WBCT with significant reductions in ED dwell time, time to diagnosis, and time to the OR.¹⁰⁻¹⁴

The ability to expedite diagnosis and treatment decisions in patients with multiple injuries is intuitively expected to reduce mortality, but studies with liberal use of WBCT provide conflicting evidence. A meta-analysis of 7 studies (n= 25,000), demonstrated a significantly lower mortality rate for WBCT vs. selective scanning (16.9 vs. 20.3 percent, p < 0.0002), even though the WBCT group had a higher ISS.¹⁵



The pooled odds ratio for mortality rate was 0.75 favoring WBCT. The prospective Randomized Study of Early Access to CT Scanning (REACT-2) trial, however, found no differences in 24-hour, in-hospital or 30-day mortality. The ISS in the two groups was equivalent, but 36 percent of the REACT-2 study population did not have polytrauma, suggesting a lower risk population.¹⁶

The potential for increased radiation with WBCT leading to higher lifetime risk of radiation-induced cancer is a concern. The introduction of a WBCT protocol in 2008, led to significantly increased radiation doses from CT, although doses from conventional radiographs decreased, and the overall radiation dose during the entire hospital admission was not significantly different.¹⁷ Another study demonstrated a 24.5 percent reduction in radiation dose with a single acquisition WBCT protocol compared to segmented whole-body CT imaging.¹⁸ The REACT-2 trial median radiation exposure was 20.9 mSv in the WBCT group and 20.6 mSv in the selective group, a median increase in radiation equivalent to one or two chest radiographs.¹⁶

Limited information exists regarding the cost of WBCT versus selective scanning. In a hypothetical cost analysis model, the total cost of WBCT was \$15,682 versus \$17,673 for selective CT.¹⁹ In the REACT-2 Trial total hospital costs were calculated and statistical differences were not found.¹⁶

WBCT is valuable in the evaluation of adult patients with multi-region injury, and those with altered level of consciousness. It also has a role in the evaluation of awake patients following a significant mechanism of injury due to the unreliability of physical examination. Identification of clinically unsuspected or occult injuries frequently results in management changes, and a negative study may allow earlier discharge from the ED. Reduced time to diagnosis allows earlier treatment, but it is unclear whether this translates into improved survival. Costs of WBCT versus selective imaging are probably equivalent, and the amount of radiation delivered over the course of hospitalization is not significantly different between the two techniques. Improvements in CT technology, such as speed and reduced doses of radiation delivered, will make WBCT an increasingly attractive diagnostic tool.

Pediatric Considerations for WBCT

WBCT has not been widely adopted for pediatric patients due to concerns about the long-term impact of ionizing radiation. Children treated at adult trauma centers are more likely to undergo WBCT compared to pediatric trauma centers, but mortality differences are not demonstrated.²⁰ Clinical prediction models for selective use of CT in specific body regions are discussed in other sections. Clinical prediction rules for selective use of CT are routinely used in alert and examinable patients, with admission for serial exams being a useful adjunct to the initial exam and radiographic imaging. WBCT in



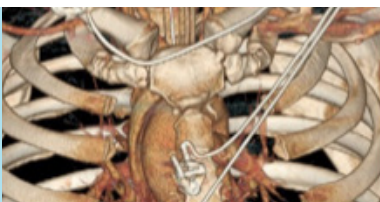
pediatric trauma centers is generally used for polytrauma patients with severe neurotrauma that impairs the ability to obtain a reliable physical examination. It is not used to screen asymptomatic children with a high-energy mechanism. When WBCT is utilized in children, multi-phase methodology for WBCT is less commonly used because venous-phase imaging of the chest and abdomen is often sufficient for screening. See other body region sections for arterial-phase imaging indications in children.

References

1. Bruns BR, Tesoriero R, Kufera J, et al. Blunt cerebrovascular injury screening guidelines: What are we willing to miss? *J Trauma Acute Care Surg.* 2014; 76(3):691-695.
2. Jacobson LE, Ziembra-Davis M, Herrera AJ. The limitations of using risk factors to screen for blunt cerebrovascular injuries: The harder you look, the more you find. *World J Emerg Surg.* 2015; 10: 46.
3. Treskes K, Saltzherr TP, Luitse JSK, Beenen LFM, Goslings JC. Indications for total-body computed tomography in blunt trauma patients: A systematic review. *Eur J Trauma Emerg Surg.* 2017; 43: 35-42.
4. Beal AL, Ahrendt MN, Irwin ED, et al. Prediction of blunt traumatic injuries and hospital admission based on history and physical exam. *World J Emerg Surg.* 2016; 11(1): 46.
5. Salim A, Sangthong B, Martin M, Plurad D, Demetriades D. Whole body imaging in blunt multisystem trauma patients without obvious signs of injury: Results of a prospective study. *Arch Surg.* 2006; 141(5): 468-475.
6. van Vugt R, Kool DR, Deunk J, Edwards MJ. Effects on mortality, treatment, and time management as a result of routine use of total body computed tomography in blunt high-energy trauma patients. *J Trauma Acute Care Surg.* 2012; 72(3): 553-559.
7. Self ML, Blake AM, Whitley M, Nadalo L, Dunn E. The benefit of routine thoracic, abdominal, and pelvic computed tomography to evaluate trauma patients with closed head injuries. *Am J Surg.* 2003; 186(6): 609-614.
8. Livingston DH, Lavery RF, Passannante M, Skurnick TC, Fry DE, Malangoni MA. Admission or observation is not necessary after a negative abdominal computed tomographic scan in patients with suspected blunt abdominal trauma: Results of a prospective, multi-institutional trial. *J Trauma.* 1998; 44(2): 273-280; discussion 280-282.
9. Livingston DH, Lavery RF, Passannante M, et al. Emergency department discharge of patients with a negative cranial computed tomography scan after minimal head injury. *Ann Surg.* 2000; 232(1): 126-132.
10. Surendran A, Mori A, Varma DK, Gruen RL. Systematic review of the benefits and harms of whole-body computed tomography in the early management of multitrauma patients: Are we getting the whole picture? *J Trauma Acute Care Surg.* 2014; 76(4): 1122-1130.
11. Weninger P, Mauritz W, Fridrich P, et al. Emergency room management of patients with blunt major trauma: Evaluation of the multislice computed tomography protocol exemplified by an urban trauma center. *J Trauma.* 2007; 62(3): 584-591.
12. Wurmb TE, Fruhwald P, Hopfner W, et al. Whole-body multislice computed tomography as the first line diagnostic tool in patients with multiple injuries: The focus on time. *J Trauma.* 2009; 66(3): 658-665.
13. Wurmb TE, Quaisser C, Balling H, et al. Whole-body multislice computed tomography (MSCT) improves trauma care in patients requiring surgery after multiple trauma. *Emerg Med J.* 2011; 28(4): 300-304.
14. Hutter M, Woltmann A, Hierholzer C, Gartner C, Buhren V, Stengel D. Association between a single-pass whole-body computed tomography policy and survival after blunt major trauma: A retrospective cohort study. *Scand J Trauma Resusc Emerg Med.* 2011; 19: 73.
15. Caputo ND, Stahmer C, Lim G, Shah K. Whole-body computed tomographic scanning leads to better survival as opposed to selective scanning in trauma patients: A systematic review and meta-analysis. *J Trauma Acute Care Surg.* 2014; 77(4): 534-539.
16. Sierink JC, Treskes K, Edwards MJR, et al. Immediate total-body CT scanning versus conventional imaging and selective CT scanning in patients with severe trauma (REACT-2): A randomised controlled trial. *Lancet.* 2016; 388(10045): 673-683.
17. Siernik JC, Saltzherr TP, Wirtz MR, Streekstra GJ, Beenen LF, Goslings JC. Radiation exposure before and after the introduction of a dedicated total-body CT protocol in multitrauma patients. *Emerg Radiol.* 2013; 20(6): 507-512.



18. Sedlic A, Chingkoie CM, Tso DK, Galea-Soler S, Nicolaou S. Rapid imaging protocol in trauma: a whole-body dual-source CT scan. *Emerg Radiol.* 2013; 20(5): 401-408.
19. Lee WS, Parks NA, Garcia A, Palmer BJA, Liu TH, Victorino GP. Pan computed tomography versus selective computed tomography in stable, young adults after blunt trauma with moderate mechanism: A cost-utility analysis. *J Trauma Acute Care Surg.* 2014; 77: 527-533.
20. Pandit V, Michailidou M, Rhee P, et al. The use of whole body computed tomography scans in pediatric trauma patients: Are there differences among adults and pediatric centers? *J Pediatr Surg.* 2016; 51(4): 649-53.



10. IMAGING IN ORTHOPAEDIC TRAUMA

Key Points

- Pelvic radiographs are important to obtain during the initial evaluation of the patient with multiple injuries, because pelvic ring injuries can be life-threatening.
- Plain radiographs should include AP and lateral views of long bones and three-views for joints.
- Consider pelvic CT with 3D reconstructions in complex pelvic fractures.
- CT is valuable in pre-operative planning for complicated fractures, such as peri-articular fractures in which intra-articular involvement is suspected.
- Pediatric fractures can occur without radiographic abnormalities.
- Perform imaging of the non-injured limb, as well as the injured limb, on a case-by-case basis.

More than 60 percent of trauma patients have injuries involving the musculoskeletal system, and more than half of hospitalized trauma patients have at least one musculoskeletal injury that could be life-threatening, limb-threatening, or result in significant functional impairment.¹ Appropriate imaging of orthopaedic injuries is essential to determine the best method of treatment.

Initial Assessment

Plain radiographs are the standard and most cost-effective imaging modality for screening and characterizing osseous injuries. Pelvic radiographs remain an integral part of the initial evaluation of the patient with multiple injuries, because pelvic ring injuries can be life-threatening. Do not delay the pelvic radiograph until the secondary survey. In addition, do not consider the pelvic CT as a substitute unless it can be performed and reviewed with the same rapidity as a pelvic radiograph.

Following the secondary survey, additional radiographs of the extremities are indicated to evaluate swelling, pain, tenderness, and deformity, to identify potential fractures or dislocations, and to evaluate penetrating wounds for retained foreign bodies.

Radiographs

In hemodynamically stable patients not requiring immediate operative intervention or interventional radiology (IR) bleeding control, obtain radiographs of the limbs using “rule of twos.”²

- Two views - Obtain AP and lateral views of the injured limb (these views are 90° orthogonal to each other); depending on the area involved, see Table 6 for specific additional radiographs to obtain.
- Two joints - When an injury occurs to an extremity, a general rule is to obtain radiographs of the joints above and below the injury to rule out any potential associated fracture or dislocation in a corresponding joint.



- Two limbs - After consultation with the orthopaedic surgeon, a request for radiographs of the injured and non-injured limbs is made to aid in evaluation and diagnosis of certain injuries. This is especially important to aid in determining limb length and rotation in pediatric patients with epiphyseal-plate injuries or in patients with severe comminuted fractures.
- Two times - Pre- and post-reduction images are needed to assess the adequacy of any fracture or dislocation manipulation or reduction.

Describe the findings of these radiographs in terms of the “rule of six”:²

- Anatomy (for example, proximal tibia)
- Articular aspect (for example, intra- vs. extra-articular)
- Alignment (for example, first plane)
- Angulation (for example, second plane)

- Apex (in terms of the distal fracture fragment)
- Apposition (for example, 75 or 0 percent [bayonet])

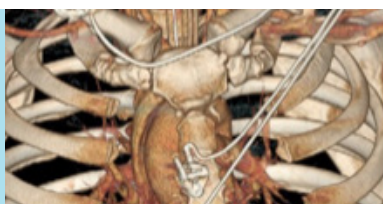
Computed Tomography and Magnetic Resonance Imaging

CT is not indicated for the routine evaluation of common fractures.³⁻⁵ However, CT can be invaluable in pre-operative planning for complicated fractures, depending on the bones involved and the degree of comminution. Pre-operative planning is critical in peri-articular fractures in which intra-articular involvement is suspected, such as acetabulum,⁶ pelvis,⁷ tibial plateau,⁸ patella,⁹ calcaneus,¹⁰ talus, tri-malleolar ankle,¹¹ and carpal bone fractures.¹² CT can also be an important adjunct for assessing fracture reduction and fixation.

MRI is uniquely able to visualize certain injuries of bone, cartilage, bone marrow, and supporting soft tissue structures;¹³ however, it is rarely indicated in patients with poly-trauma due to the excessive

Table 6. Potential Additional Radiographic Images to Obtain in Addition to Standard AP and Lateral after Consultation with the Orthopaedic Surgeon and/or Radiologist

Body Region	Additional Images
Upper extremity	<ul style="list-style-type: none"> ● Shoulder or glenohumeral joint – Axillary view ● Clavicle – Upright AP in 30° cephalic tilt ● Scapula – Y view ● Comminuted elbow – Traction view ● Scaphoid – Postero-anterior (PA) in ulnar deviation
Pelvis and hip	<ul style="list-style-type: none"> ● Pelvis – Inlet and outlet views ● Acetabulum – Iliac oblique, obturator oblique (Judet views) ● Femoral neck – AP view with 15° internal rotation ● Hip – Traction view
Lower extremity	<ul style="list-style-type: none"> ● Knee joint – Notch view and/or Merchant view ● Ankle joint – Mortise view ● Calcaneus – Harris heel view ● Talus – Canale view



time required for imaging and its cost. For patients without systemic injuries, MRI offers exquisitely detailed anatomical information on the musculoskeletal system. MRI is valuable in the evaluation of specific musculoskeletal trauma, including hemarthrosis; lipoarthrosis; stress fracture; occult fractures; pathologic fractures; cartilage injuries; muscle, tendon, and ligamentous injuries; avulsion injuries; extensor mechanism injuries; and joint trauma.¹⁴

Ultrasound is a non-invasive, time-efficient adjunct for soft tissue imaging of the musculoskeleton that is being used more frequently.¹⁵ It is particularly useful in evaluating tendon tears (such as, Achilles) that cannot be diagnosed with plain radiographs.

Pediatric Orthopaedic Injuries

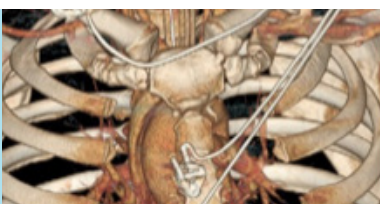
Plain radiography remains the standard and most cost-effective imaging for screening and characterizing osseous injuries, but it is well recognized that pediatric fractures can occur without radiographic abnormalities. The capability of MRI to demonstrate marrow edema, cartilage defects, and soft tissue injuries makes it an important adjunct in the further evaluation of trauma to the growing skeleton. The value of MRI is especially noted in finding growth plate injuries, stress fractures, avulsion injuries, osteochondritis dissecans, transient patellar dislocation, and soft tissue injuries. An acute MRI is rarely required.¹⁶

References

1. Ruedi TP, Buckley R, Moran C, eds. *AO Principles of Fracture Management*. 2nd ed. New York, NY: Thieme Medical Publishers, Inc; 2007.
2. Tornetta P III, Court-Brown C, Heckman JD, McKee M, McQueen MM, Ricci W. *Rockwood and Green's Fractures in Adults*. 8th ed. Philadelphia, PA; Lippincott Williams & Wilkins; 2014.
3. Brox WT, Roberts KC, Taksali S, et al. The American Academy of Orthopaedic Surgeons Evidence-based Guideline on Management of Hip Fractures in the Elderly. *J Bone Joint Surg Am*. 2015 Jul 15; 97(14): 1196-1199.
4. Vallier, HA; Ahmadinia, K; Forde, FA; Ekstein, C; Nash, CL; Tornetta, P. Trends in musculoskeletal imaging in trauma patients: How has our practice changed over time? *Journal of Orthopaedic Trauma*. 2014; 28(10): e236–e241.
5. Natoli R.M, Fogel HA, Holt D, et al. Advanced imaging lacks clinical utility in treating geriatric pelvic ring injuries caused by low-energy trauma. *Journal of Orthopaedic Trauma*. April 2017; 31(4): 194–199.
6. Davis, AT; Moed, BR. Can experts in acetabular fracture care determine hip stability after posterior wall fractures using plain radiographs and computed tomography? *Journal of Orthopaedic Trauma*. 2013; 27(10): 587–591.
7. McAndrew, CM; Merriman, DJ; Gardner, MJ; Ricci, WM. Standardized posterior pelvic imaging: Use of CT inlet and CT outlet for evaluation and management of pelvic ring injuries. *Journal of Orthopaedic Trauma*. 2014; 28(12): 665–673.
8. Chan, PSH; Klimkiewicz, JJ; Luchetti, WT, et al.. Impact of CT scan on treatment plan and fracture classification of tibial plateau fractures. *Journal of Orthopaedic Trauma*. 1997; 11(7): 484-489.
9. Lazaro, LE; Wellman, DS; Pardee, NC, et al. Effect of computerized tomography on classification and treatment plan for patellar fractures, *Journal of Orthopaedic Trauma*. 2013; 27(6): 336–344.
10. Badillo K, Pacheo, JA, Padua SO, Gomez AA, Colon E, Vidal JA. Multidetector CT evaluation of calcaneal fractures. *RadioGraphics*. 2011; 31:81-92.
11. Gibson, PD; Bercik, MJ; Ippolito, JA, et al. The role of computed tomography in surgical planning for trimalleolar fracture. A survey of OTA Members. *Journal of Orthopaedic Trauma*. 2017; 31(4): e116–e120.



12. Kaewlai R, Avery LL, Asrani AV, Abujudeh HH, Sacknoff R, Novelline RA. Multidetector CT of carpal injuries: Anatomy, fractures, and fracture-dislocations. *RadioGraphics*. 2008; 28(6): 1771-1784.
13. Eustace S1, Adams J, Assaf A. Emergency MR imaging of orthopaedic trauma. Current and future directions. *Radiology Clinics of North America*. 1999 Sep; 37(5): 975-94.
14. Ahn JM, El-Khoury GY. Role of magnetic resonance imaging in musculoskeletal trauma. *Top Magn Reson Imaging*. 2007 Jun; 18(3): 155-68.
15. McManus JG, Morton MJ, Crystal CS, et al. Use of ultrasound to assess acute fracture reduction in emergency care settings. *Am J Disaster Med*. 2008 Jul-Aug; 3(4): 241-7.
16. Sanchez TR1, Jadhav SP, Swischuk LE. MR imaging of pediatric trauma. *Magn Reson Imaging Clin N Am*. 2009 Aug; 17(3): 439-50.



11. IMAGING FOR EXTREMITY VASCULAR INJURY

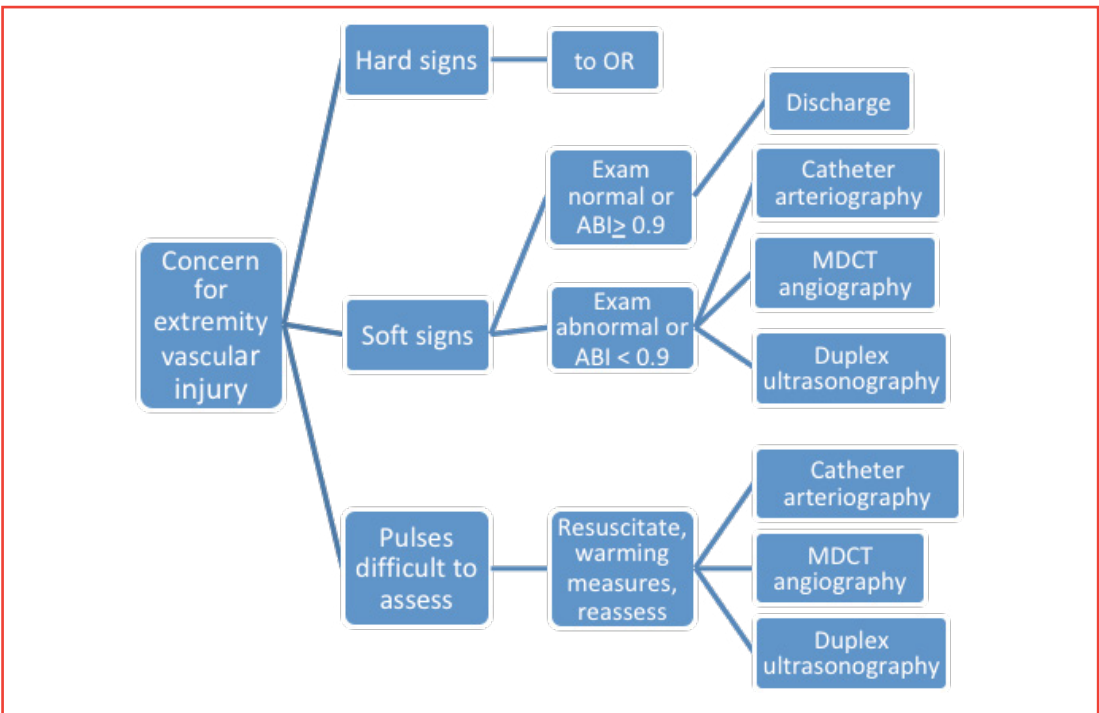
Key Points

- Before imaging, reduce the fracture or dislocation, if present, and appropriately splint the patient’s limb to fully assess the vascular status.
- Hard signs of a vascular injury require immediate operative management.
- In patients with soft signs of vascular injury and ankle brachial index (ABI) less than 0.9, perform CTA.

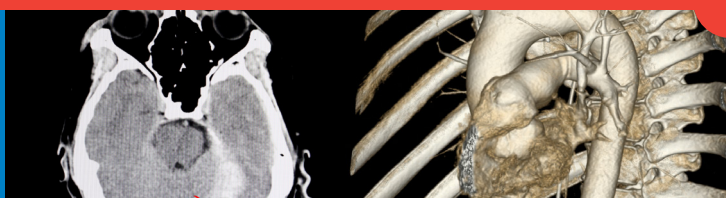- For CTA of the extremity use at least a 64 slice MDCT.
- Obtaining completion angiography following repair of a vascular injury is strongly advisable.
- Traditional angiography may be required to evaluate distal vessels of pediatric patients due to significant vasospasm in younger patients.

The decision to perform imaging studies to evaluate a potential extremity vascular injury is dependent on the patient’s presentation.¹⁻³ See Figure 5 for guidance in the evaluation of patients suspected of having an extremity vascular injury.

Figure 5. Extremity Vascular Injury Evaluation



Data from: Feliciano DV; Moore FA, Moore EE, et al. Evaluation and management of peripheral vascular injury. Part 1. Western Trauma Association/Critical Decisions in Trauma. *J Trauma*. June 2011; 70(6): 1551-1556; Seamon MJ, Smoger D, Torres DM, et al. A prospective validation of a current practice: The detection of extremity vascular injury with CT angiography. *J Trauma*. 2009; 67(2): 238-244; and Fox N, Rajani R, Bokhari F, et al. Evaluation and management of penetrating lower extremity arterial trauma: An Eastern Association for the Surgery of Trauma practice management guideline. *J Trauma Acute Care Surg*. 2012; 73(5): S315-S320.



Before performing vascular imaging, a displaced fracture or dislocation if present should be reduced and splinted to fully assess the vascular status.

CT Arteriography

The presence of hard signs of a vascular injury requires the patient to go immediately to the OR (see Table 7). Of this group, on-table angiography is indicated when urgent evaluation for localization of the lesion is indicated as in blast injuries, shotgun wounds, and in cases of multiple extremity fractures.⁴⁻⁶

In patients with soft signs (Table 7), an ABI is measured.^{7,8} If the ABI is less than 0.9, perform CTA.⁹⁻¹¹ For CTA of the extremity, a 16 slice MDCT is adequate, but 64 slice MDCT is optimal.¹² CTA signs of vascular injury in extremity trauma include:

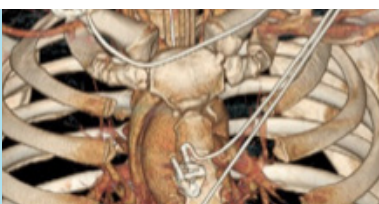
- Lack of vessel opacification indicating occlusion of an arterial segment
- Active contrast extravasation
- An extravascular collection containing contrast

- Abrupt vessel narrowing
- Intraluminal filling defect or intimal irregularity
- Early venous opacification indicating an arteriovenous fistula
- Abnormal change in vessel caliber, contour, or course

Vessel caliber reduction on CTA can indicate the presence of spasm, dissection, or external compression. Lumen narrowing with irregular contour is a sign of a partial-thickness wall injury and thrombus. Abnormal caliber change can be subtle, especially in the distal lower extremities, where the native lumen normally tapers and the limits of CTA resolution are approached. Ensure that CTA sagittal and coronal reformations and 3D reconstructions are reviewed. Maximum intensity projection (MIP) images may be produced for better visualization of the vascular anatomy and injury.¹³⁻¹⁵

Table 7. Signs of Extremity Vascular Injury

Hard signs	<ul style="list-style-type: none"> ● External bleeding ● A rapidly expanding hematoma ● Any of the classical signs of arterial occlusion: pulselessness, pallor, paresthesia, pain, paralysis (five Ps) ● A palpable thrill or audible bruit
Soft signs	<ul style="list-style-type: none"> ● Neurologic injury in proximity to vessel ● Hematoma ● History of moderate hemorrhage ● Diminished but palpable pulse ● Injury proximity (fracture, dislocation, or penetrating wound)



Keep several potential pitfalls in mind when interpreting CTA of the extremities, including the following:¹⁵

- Suboptimal contrast attenuation in the vessel lumen
- Incomplete vessel opacification because of discrepancy between transit of the contrast bolus and timing of the image acquisition
- Vessel under-filling from slow flow as a result of injury further upstream
- Vessel spasm
- Anatomic variants
- Underlying atherosclerosis
- Displaced fracture fragments
- Artifacts from metal, foreign bodies, and patient motion or positioning constraints

Determine if the image quality is adequate to confidently evaluate an arterial segment for injury due to adjacent metallic foreign bodies or orthopaedic hardware.¹⁶ If image quality is inadequate, individualize the decision to proceed with CTA or repeating CTA versus formal catheter-based arteriography.

Duplex Doppler examination of the extremity is an alternative imaging study for the patient with soft signs and an ABI less than 0.9. Accurate performance of these studies is very dependent on the expertise of the technologist, making its routine use facility dependent.¹⁷

Digital subtraction angiography continues to play an important role in the evaluation and management of extremity vascular injuries. Many trauma centers now have Hybrid ORs equipped with this capability, allowing for endovascular repair for selective injuries.¹⁸ Endovascular technology and techniques continue to evolve for use in the management of some traumatic vascular injuries.¹⁹

When this state-of-the-art equipment is not available, using a portable digital fluoroscopy unit in the OR is adequate in most instances. Obtaining extremity arteriograms with a portable radiograph machine can be used, but it seems to be a lost art. The key to success is in determining the proper timing of the bolus and obtaining the image. No matter what equipment is available, obtaining completion angiography following repair of a vascular injury is strongly advisable.

Pediatric Considerations

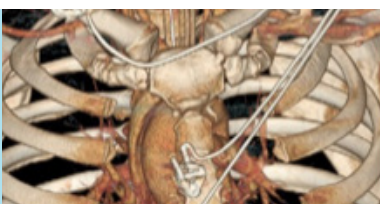
Extremity vascular imaging in the pediatric population is similar to that of adults. However, vasospasm cannot be reliably diagnosed by CTA, requiring catheter angiography. If imaging of the pediatric patient's distal vessels is required, consider using traditional angiography.²⁰

References

1. Feliciano DV; Moore FA, Moore EE, et al. Evaluation and management of peripheral vascular injury. Part 1. Western Trauma Association/Critical Decisions in Trauma. *J Trauma*. June 2011; 70(6): 1551-1556.
2. Mattox KL, Feliciano DV, Burch J, Beall AC Jr, Jordan GL Jr, De Bakey ME. Five thousand seven hundred sixty cardiovascular injuries in 4459 patients. Epidemiologic evolution 1958 to 1987. *Ann Surg*. 1989; 209: 698-707.



3. Rozycki GS, Tremblay LN, Feliciano DV, McClelland WB. Blunt vascular trauma in the extremity: Diagnosis, management, and outcome. *J Trauma*. 2003; 55: 814–824.
4. Callcut RA, Acher CW, Hoch J, Tefera G, Turnipseed W, Mell MW. Impact of intraoperative arteriography on limb salvage for traumatic popliteal artery injury. *J Trauma*. 2009; 67: 252–258.
5. Itani KMF, Burch JM, Spjut-Patrinely V, Richardson R, Martin RR, Mattox KL. Emergency center arteriography. *J Trauma*. 1992; 32: 302–307.
6. O’Gorman RB, Feliciano DV. Arteriography performed in the emergency center. *Am J Surg*. 1986; 152: 323–325.
7. Dennis JW, Frykberg ER, Veldenz HC, Huffman S, Menawat SS. Validation of nonoperative management of occult vascular injuries and accuracy of physical examination alone in penetrating extremity trauma: 5-to-10-year follow-up. *J Trauma*. 1998; 44: 243–253.
8. Lynch K, Johansen K. Can Doppler pressure measurement replace “exclusion” arteriography in the diagnosis of occult extremity arterial trauma? *Ann Surg*. 1991; 214: 737–741.
9. Rieger M, Mallouhi A, Tauscher T, Lutz M, Jaschke W. Traumatic arterial injuries of the extremities: Initial evaluation with MDCT angiography. *AJR*. 2006; 186: 656–664.
10. Inaba K, Potzman J, Munera F, et al. Multi-slice CT angiography for arterial evaluation in the injured lower extremity. *J Trauma*. 2006; 60: 502–506.
11. Soto JA, Múnera F, Morales C, et al. Focal arterial injuries of the proximal extremities: Helical CT arteriography as the initial method of diagnosis. *Radiology*. 2001; 218: 188–194.
12. Fishman EK, Horton KM, Johnson PT. Multidetector CT and three-dimensional CT angiography for suspected vascular trauma of the extremities. *RadioGraphics*. 2008; 28: 653–665.
13. Peng PD, Spain DA, Tataria M, Hellinger JC, Rubin GD, Brundage SI. CT angiography effectively evaluates extremity vascular trauma. *Am Surg*. 2008; 74: 103–107.
14. Hallett LH, Fleischmann D. Tools of the trade for CTA: MDCT scanners and contrast medium injection protocols. *Tech Vasc Interventional Radiol*. 2006; 9: 134–142.
15. Miller-Thomas MM, West OC, Cohen AM. Diagnosing traumatic arterial injury in the extremities with CT angiography: Pearls and pitfalls. *RadioGraphics*. 2005; 25: S133–S142.
16. Lee MJ, Kim S, Lee SA, et al. Overcoming artifacts from metallic orthopaedic implants and high- field-strength MR imaging and multi-detector CT. *RadioGraphics*. 2007; 27: 791–803.
17. Knudson MM, Lewis FR, Atkinson K, Neuhaus A. The role of duplex ultrasound arterial imaging in patients with penetrating extremity trauma. *Arch Surg*. 1993; 128: 1033–1038.
18. Compton C, Rhee R. Peripheral vascular trauma. *Perspect Vasc Surg Endovasc Ther*. 2005; 17: 297-307.
19. Branco BC, DuBose JJ, Zhan LX, et al. Trends and outcomes of endovascular therapy in the management of civilian vascular injuries. *J Vasc Surg*. 2014; 60(5): 1297-1307.
20. Heinzerling NP, Sato TT. Pediatric Vascular Injuries. In: Dua A, Desai S, Holcomb J, Burgess A, Freischlag J (eds). *Clinical Review of Vascular Trauma*. Berlin, Germany: Springer; 2014.



12. INTERVENTIONAL RADIOLOGY FOR TRAUMATIC INJURIES

Key Points

- The Society of Interventional Radiology develops and publishes practice standards pertaining to diagnostic angiography, pediatric angiography, angioembolization, resources and environment of care, and staffing.
- Angioembolization (AE) is an important component of salvaging injured organs, such as the spleen, kidney, and liver, utilizing minimally invasive measures.
- Consider using AE of the spleen in adult patients who are hemodynamically stable with AAST Grade 3 or higher injury, contrast extravasation or pseudoaneurysm, hemoperitoneum, or evidence of ongoing hemorrhage.
- AE may have a role in selected pediatric patients to increase splenic salvage; however, specific indications are not reported regarding AE based on injury grade or contrast extravasation.
- Consider AE as initial treatment for patients with a pelvic fracture who are hemodynamically unstable and have no indication for laparotomy or other source of hemorrhage.

General Guidelines

Interventional radiology is an integral part of trauma patient management with the evolution of nonoperative management for specific injuries in carefully selected patients. A robust and engaged IR department is an essential complement to surgical services in the management of trauma patients. Established IR practice standards pertaining to diagnostic angiography, pediatric angiography, angioembolization, resources and environment of care, and staffing are published in the *Journal of Vascular and Interventional Radiology*.¹⁻⁶

The Society of Interventional Radiology develops these practice standards, the details of which are beyond the scope of this document. Important aspects of these practice standards address staffing requirements, the environment of care, procedural indications, contraindications, success rates, complication rates, training standards, and radiation safety.¹⁻⁶

Included within the staffing guidelines is a recommendation to determine time to intervention. This is in accordance with initiatives (for example, trauma and stroke center verification) that attempt to improve patient outcomes.² *Resources for the Optimal Care of the Injured Patient* states that for Level I and II ACS-verified trauma centers, radiologists are to be available for interventions within 30 minutes. Time to intervention is tracked and coupled with a robust PI program.⁷

The availability of interventional radiology services 24 hours a day is essential to treat traumatic hemorrhage in a variety of vascular beds. A rapid response time by the IR team and time to intervention is



important to improve the outcomes of patients with severe trauma, particularly when hemorrhage is from a pelvic arterial source. Angioembolization is also an important component of salvaging injured organs, such as the spleen, kidney, and liver, utilizing minimally invasive measures.

A useful asset to a trauma center's ability to manage complex trauma is a hybrid OR that has both angiography and surgical capabilities. This allows rapid transition between operative and endovascular procedures without the risks associated with transferring the patient, especially to an area that may be less equipped to manage the many simultaneous requirements of a patient with severe trauma. Laparotomy with packing, as needed, can be followed rapidly by catheter angiography of areas, such as the liver and pelvis, with poorly controlled hemorrhage identified surgically. Retroperitoneal hematomas can also be identified and treated with angiographic or endovascular intervention. If the patient requires further operative procedures following an endovascular intervention, this transition is also accommodated more smoothly in the operating room environment.

Solid Organs

Spleen

The precise role of AE for hemostasis of blunt splenic trauma remains controversial. Multiple studies using similar patient groups have differing results. For this reason, trauma centers need center-specific protocols for the

management of these injuries that are tracked in the PI program that monitors patient outcomes.⁸ Most studies used AAST organ system grading to define the severity of splenic injury and groups at risk for hemorrhage. Other studies looked at patient factors such as hemoperitoneum, hypotension, or tachycardia.⁸⁻¹⁴ Additionally, AE is guided by cross-sectional imaging with CT scan. Improvements in scanner technology have increased identification of even minor vascular injuries, leading to questions about how these injuries correlate with the need for AE. Weigh any possible improvement in splenic salvage against the risks of AE, including pain, abscess, and access complications.¹⁵⁻²⁰

Consider using AE of the spleen in patients who are hemodynamically stable with AAST Grade 3 or higher injury, contrast extravasation or pseudoaneurysm, hemoperitoneum, or evidence of ongoing hemorrhage.^{8,21} Contrast extravasation on CT scan alone, does not mandate AE, but considers it along with other factors such as grade of injury, hemodynamics, and concern for rebleeding. This is particularly true in the pediatric patient. AE is successfully used in pediatrics to increase splenic salvage; however, specific indications in the pediatric population are unknown.^{11,12,19,22-27}

Both proximal and distal arterial embolization of the splenic artery have been described. Proximal embolization of the splenic artery with coils or vascular plugs allows collateral flow to perfuse the spleen while decreasing the arterial pressure head to facilitate intrinsic



hemostasis. Distal Gelfoam® embolization of large portions or the entire organ causes parenchymal infarction and increases the risk of abscess formation. Subselective embolization of a large, focal pseudoaneurysm or a vessel with brisk intraperitoneal hemorrhage is sometimes indicated; however, this must be completed prior to proximal embolization to prevent blocking access to the injured vessel before the injury is adequately treated.²⁸

Routine post-discharge imaging after splenic embolization in the asymptomatic patient is not recommended.^{14,29-31}

Liver

AE of the liver is an important adjunct in nonoperative management of traumatic arterial hemorrhage.³² Because venous hemorrhage from the liver plays a significant role, AE alone may not be sufficient. Initially manage patients who are hemodynamically unstable with indication for laparotomy by hepatic packing or a Pringle maneuver in the OR. Consider AE if arterial hemorrhage is difficult to control by surgery or continued arterial bleeding from a significantly damaged liver parenchyma is found.^{33,34}

Patients who are hemodynamically stable may have liver injury identified on cross-sectional imaging. Consider AE for patients with active, arterial contrast extravasation on CT. Also consider AE for patients who are transient responders to resuscitation with a vascular injury, but no other indication for laparotomy.^{13,34} In the pediatric population, active

extravasation in the patient who is hemodynamically stable may not be a sufficient indicator of the need for AE. Be as selective as possible with AE in the pediatric patient to decrease the risk of hepatic necrosis.^{25,27,35,36}

Take care when embolizing proximally within the hepatic artery as gallbladder necrosis has been reported. Special consideration is important for patients with known liver disease or underlying cirrhosis. In these cases, determine residual hepatic function before proximal embolization of large areas of hepatic circulation. It is important to leave patients with sufficient hepatic function to prevent liver failure.^{32,37}

While not usually necessary, consider repeat embolization of the liver in patients with ongoing blood loss. Evaluate for other sources of hemorrhage as well.¹³

Kidney

Nonoperative management is the treatment of choice for the majority of blunt renal injury.^{38,39} AE has an increasing, but limited, role in renal trauma.^{40,41} Consider AE for patients with renal trauma with hemodynamic instability and no other indication for laparotomy, active extravasation or pseudoaneurysm on CT, persistent or recurrent hematuria after renal trauma, or expanding retroperitoneal hematoma that is not surgically explored.^{38,40,42} Renal arteries are end-organ vessels and do not have a robust collateral circulation. All renal embolization must be as subselective as possible to preserve as much organ function as possible. Coils



and possibly liquid embolic agents are preferred, although in some cases Gelfoam® is an appropriate agent.

Renal artery thrombosis is an uncommon result of blunt trauma. The underlying injury may be dissection or transection. If no other injuries with a higher priority exist, consider endovascular treatment for organ preservation.⁴³ The appropriate window of treatment is reported to be less than 6 hours from injury, but minimizing the ischemic time is ideal. Use stents or stent grafts to repair the arterial injury and re-establish arterial blood flow. Anticoagulation is recommended in appropriate patients. The inability to anticoagulate trauma patients may contribute to the inconsistent results with stenting.⁴⁴

Pelvis

AE plays an important role in controlling life-threatening hemorrhage from pelvic fracture.^{45,46} The initial management of the bleeding pelvis without indication for laparotomy varies by local protocols. Many trauma centers use angiography while others proceed with immediate operative pelvic packing.^{45,47,48} All facilities need a protocol for the management of patients with pelvic fractures that includes a PI process because time to AE impacts outcome.^{49,50} Consider AE as initial treatment for patients with a pelvic injury stabilized by a sheet or binder who are still hemodynamically unstable and have no indication for laparotomy or other source of hemorrhage.^{45,46} AE may

be performed in combination with pelvic reduction, however, the local availability of these resources must be considered. If the patient's pelvis is adequately stabilized with a sheet or binder, hardware fixation is not immediately necessary. In addition, consider AE in all patients with pelvic fracture and contrast extravasation on CT scan, regardless of hemodynamics.⁵¹ Repeat AE for patients who have previously undergone AE of the pelvis and have ongoing hemorrhage.⁵²⁻⁵⁴ Also consider AE for patients with pelvic fracture who have undergone pre-peritoneal packing and have ongoing hemorrhage.^{45,47} When possible, perform selective angiography of the bleeding vessel; however, in cases of severe injury or diffuse pelvic bleeding, this is not always possible. In such cases, embolization of the entire internal iliac system can be performed.⁵⁵⁻⁵⁸

Arterial bleeding is intermittent and injured vessels can vasoconstrict, so bleeding may not be apparent at the moment of arteriogram. When a patient has no evidence of arterial extravasation, the decision for prophylactic AE is made on the basis of several factors.⁵⁵ Patients who are not embolized but show subsequent signs of ongoing hemorrhage may require repeat angiographic imaging and AE.⁵⁹

Treat elderly patients more aggressively with AE than younger individuals with a negative angiogram because of less ability to tolerate hemorrhage and/or hypotension due to lack of cardiovascular reserve.⁶⁰



Consider prophylactic internal iliac artery embolization for unstable patients with ongoing transfusion requirements when no specific site of hemorrhage is identified.

Other Vascular Beds

AE is utilized in almost all vascular beds. Retroperitoneal, chest wall, and extremity arterial embolization is appealing in these cases: the source of bleeding cannot be identified surgically or is in a difficult to access location; when the patient is unable to tolerate further surgical interventions; or any time minimally invasive treatment is preferred to surgical options. These procedures may be necessitated by findings on CT scans, operative findings, or in the nonoperative observation period if a patient fails conservative management. No systematic studies of embolization of these less common embolization sites are published, but case reports and single trauma center papers discuss the feasibility and results of intercostal and lumbar artery embolization.⁶¹⁻⁶³

A recent paper concludes that many small vessel abnormalities of the extremity seen on CT scan may safely be observed.⁶² For those that were treated with embolization, the procedure was safe and effective. Base the decision to proceed with embolization within these vascular beds on hemodynamics, imaging or operative findings, risks of alternative treatments, and patient characteristics on a case-by-case basis.

References

1. Angle JF, Siddiqi NH, Wallace MJ, et al. Society of Interventional Radiology Standards of Practice Committee: Quality improvement guidelines for percutaneous transcatheter embolization. *J Vasc Interv Radiol.* 2010; 21(10): 1479-1486. doi:10.1016/j.jvir.2010.06.014.
2. Baerlocher MO, Kennedy SA, Ward TJ, et al. Society of Interventional Radiology Position Statement: Staffing guidelines for the interventional radiology suite. *J Vasc Interv Radiol.* 2016; 27(5): 618-622. doi:10.1016/j.jvir.2016.02.010.
3. Baerlocher MO, Kennedy SA, Ward TJ, et al. Society of Interventional Radiology: Resource and environment recommended standards for IR. *J Vasc Interv Radiol.* 2017; 28(4): 513-516. doi:10.1016/j.jvir.2016.12.1213.
4. Dariushnia SR, Gill AE, Martin LG, et al. Quality improvement guidelines for diagnostic arteriography. *J Vasc Interv Radiol.* 2014; 25(12): 1873-1881. doi:10.1016/j.jvir.2014.07.020.
5. Golzarian J, Sapoval MR, Kundu S, et al. Guidelines for peripheral and visceral vascular embolization training: Joint writing groups of the Standards of Practice Committees for the Society of Interventional Radiology (SIR), Cardiovascular and Interventional Radiological Society of Europe (CIRSE), and Canadian Interventional Radiology Association (CIRA). *J Vasc Interv Radiol.* 2010; 21(4): 436-441. doi:10.1016/j.jvir.2010.01.006.
6. Joint quality improvement guidelines for pediatric arterial access and arteriography: From the Societies of Interventional Radiology and Pediatric Radiology. *J Vasc Interv Radiol.* 2010; 21(1): 32-43. doi:10.1016/j.jvir.2009.09.006.
7. American College of Surgeons. *Resources for Optimal Care of the Injured Patient.* Chicago, IL; 2016. <https://www.facs.org/quality-programs/trauma/vrc> Accessed April 17, 2018.
8. Stassen NA, Bhullar I, Cheng JD, et al. Selective nonoperative management of blunt splenic injury: An Eastern Association for the Surgery of Trauma practice management guideline. *J Trauma Acute Care Surg.* 2012; 73(5 Suppl 4): S294-S300. doi:10.1097/TA.0b013e3182702afc.
9. Olthof DC, Joosse P, Bossuyt PMM, et al. Observation versus embolization in patients with blunt splenic injury after trauma: A propensity score analysis. *World J Surg.* 2016; 40(5): 1264-1271. doi:10.1007/s00268-015-3387-8.
10. Banerjee A, Duane TM, Wilson SP, et al. Trauma center variation in splenic artery embolization and spleen salvage: A multicenter analysis. *J Trauma Acute Care Surg.* 2013; 75(1): 69-74-discussion74-75. doi:10.1097/TA.0b013e3182988b3b.



11. Bhullar IS, Tepas JJ, Siragusa D, Loper T, Kerwin A, Frykberg ER. To nearly come full circle: Nonoperative management of high-grade IV-V blunt splenic trauma is safe using a protocol with routine angioembolization. *J Trauma Acute Care Surg.* 2017; 82(4): 657-664. doi:10.1097/TA.0000000000001366.
12. Bhullar IS, Frykberg ER, Tepas JJ, Siragusa D, Loper T, Kerwin AJ. At first blush: Absence of computed tomography contrast extravasation in Grade IV or V adult blunt splenic trauma should not preclude angioembolization. *J Trauma Acute Care Surg.* 2013; 74(1): 105-11-discussion111-2. doi:10.1097/TA.0b013e3182788cd2.
13. Melloul E, Denys A, Demartines N. Management of severe blunt hepatic injury in the era of computed tomography and transarterial embolization: A systematic review and critical appraisal of the literature. *J Trauma Acute Care Surg.* 2015; 79(3): 468-474. doi:10.1097/TA.0000000000000724.
14. Olthof DC, van der Vlies CH, van der Vlies CH, et al. Consensus strategies for the nonoperative management of patients with blunt splenic injury: A Delphi study. *J Trauma Acute Care Surg.* 2013; 74(6): 1567-1574. doi:10.1097/TA.0b013e3182921627.
15. Aiolfi A, Inaba K, Strumwasser A, et al. Splenic artery embolization versus splenectomy: Analysis for early in-hospital infectious complications and outcomes. *J Trauma Acute Care Surg.* September 2017; 83(3): 356-360. doi:10.1097/TA.0000000000001550.
16. Chastang L, Bège T, Prudhomme M, et al. Is non-operative management of severe blunt splenic injury safer than embolization or surgery? Results from a French prospective multicenter study. *J Vasc Surg.* 2015; 152(2): 85-91. doi:10.1016/j.jviscsurg.2015.01.003.
17. Ekeh AP, Khalaf S, Ilyas S, Kauffman S, Walusimbi M, McCarthy MC. Complications arising from splenic artery embolization: A review of an 11-year experience. *Am J Surg.* 2013; 205(3): 250-4-discussion254. doi:10.1016/j.amjsurg.2013.01.003.
18. Freitas G, Olufajo OA, Hammouda K, et al. Postdischarge complications following nonoperative management of blunt splenic injury. *Am J Surg.* 2016; 211(4): 744-749.e1. doi:10.1016/j.amjsurg.2015.11.018.
19. Zamora I, Tepas JJ, Kerwin AJ, Pieper P, Bhullar IS. They are not just little adults: Angioembolization improves salvage of high grade IV-V blunt splenic injuries in adults but not in pediatric patients. *Am Surg.* 2012; 78(8): 904-906.
20. Zarzaur BL, Kozar R, Myers JG, et al. The splenic injury outcomes trial: An American Association for the Surgery of Trauma multi-institutional study. *J Trauma Acute Care Surg.* 2015; 79(3): 335-342. doi:10.1097/TA.0000000000000782.
21. Crichton JCI, Naidoo K, Yet B, Brundage SI, Perkins Z. The role of splenic angioembolization as an adjunct to nonoperative management of blunt splenic injuries: A systematic review and meta-analysis. *J Trauma Acute Care Surg.* 2017; 83(5): 934-943. doi:10.1097/TA.0000000000001649.
22. Alarhayem AQ, Myers JG, Dent D, et al. "Blush at first sight": Significance of computed tomographic and angiographic discrepancy in patients with blunt abdominal trauma. *Am J Surg.* 2015; 210(6): 1104-1110-discussion1110-1111. doi:10.1016/j.amjsurg.2015.08.009.
23. Bansal S, Karrer FM, Hansen K, Partrick DA. Contrast blush in pediatric blunt splenic trauma does not warrant the routine use of angiography and embolization. *Am J Surg.* 2015; 210(2): 345-350. doi:10.1016/j.amjsurg.2014.09.028.
24. Gross JL, Woll NL, Hanson CA, et al. Embolization for pediatric blunt splenic injury is an alternative to splenectomy when observation fails. *J Trauma Acute Care Surg.* 2013; 75(3): 421-425. doi:10.1097/TA.0b013e3182995c70.
25. Ingram M-CE, Siddharthan RV, Morris AD, et al. Hepatic and splenic blush on computed tomography in children following blunt abdominal trauma: Is intervention necessary? *J Trauma Acute Care Surg.* 2016; 81(2): 266-270. doi:10.1097/TA.0000000000001114.
26. Lopez JM, McGonagill PW, Gross JL, et al. Subcapsular hematoma in blunt splenic injury: A significant predictor of failure of nonoperative management. *J Trauma Acute Care Surg.* 2015; 79(6): 957-959; discussion959-960. doi:10.1097/TA.0000000000000854.
27. Vo N-J, Althoen M, Hippe DS, Prabhu SJ, Valji K, Padia SA. Pediatric abdominal and pelvic trauma: safety and efficacy of arterial embolization. *J Vasc Interv Radiol.* 2014; 25(2): 215-220. doi:10.1016/j.jvir.2013.09.014.
28. Rong J-J, Liu D, Liang M, et al. The impacts of different embolization techniques on splenic artery embolization for blunt splenic injury: A systematic review and meta-analysis. *Mil Med Res.* 2017; 4(1): 17. doi:10.1186/s40779-017-0125-6.
29. Martin K, Vanhouwelingen L, Bütter A. The significance of pseudoaneurysms in the nonoperative management of pediatric blunt splenic trauma. *J Pediatr Surg.* 2011; 46(5): 933-937. doi:10.1016/j.jpedsurg.2011.02.031.



30. Morrison CA, Gross BW, Kauffman M, Rittenhouse KJ, Rogers FB. Overview of nonoperative blunt splenic injury management with associated splenic artery pseudoaneurysm. *Am Surg*. 2017; 83(6): 554-558.
31. Safavi A, Beaudry P, Jamieson D, Murphy JJ. Traumatic pseudoaneurysms of the liver and spleen in children: Is routine screening warranted? *J Pediatr Surg*. 2011; 46(5): 938-941. doi:10.1016/j.jpedsurg.2011.02.035.
32. Green CS, Bulger EM, Kwan SW. Outcomes and complications of angioembolization for hepatic trauma: A systematic review of the literature. *J Trauma Acute Care Surg*. 2016; 80(3): 529-537. doi:10.1097/TA.0000000000000942.
33. Sivrikoz E, Teixeira PG, Resnick S, Inaba K, Talving P, Demetriades D. Angiointervention: An independent predictor of survival in high-grade blunt liver injuries. *Am J Surg*. 2015; 209(4): 742-746. doi:10.1016/j.amjsurg.2014.06.024.
34. Stassen NA, Bhullar I, Cheng JD, et al. Nonoperative management of blunt hepatic injury: An Eastern Association for the Surgery of Trauma practice management guideline. *J Trauma Acute Care Surg*. 2012; 73(5 Suppl 4): S288-S293. doi:10.1097/TA.0b013e318270160d.
35. Ong CCP, Toh L, Lo RHG, Yap T-L, Narasimhan K. Primary hepatic artery embolization in pediatric blunt hepatic trauma. *J Pediatr Surg*. 2012; 47(12): 2316-2320. doi:10.1016/j.jpedsurg.2012.09.050.
36. Kong Y-L, Zhang H-Y, He X-J, et al. Angiographic embolization in the treatment of intrahepatic arterial bleeding in patients with blunt abdominal trauma. *HBPD INT*. 2014; 13(2): 173-178.
37. Kozar RA, Moore FA, Cothren CC, et al. Risk factors for hepatic morbidity following nonoperative management: Multicenter study. *Arch Surg*. 2006; 141(5): 451-458-discussion458-459. doi:10.1001/archsurg.141.5.451.
38. Bryk DJ, Zhao LC. Guideline of guidelines: A review of urological trauma guidelines. *BJU Int*. 2016; 117(2): 226-234. doi:10.1111/bju.13040.
39. LeeVan E, Zmora O, Cazzulino F, Burke RV, Zagory J, Upperman JS. Management of pediatric blunt renal trauma: A systematic review. *J Trauma Acute Care Surg*. 2016; 80(3): 519-528. doi:10.1097/TA.0000000000000950.
40. Hotaling JM, Sorensen MD, Smith TG, Rivara FP, Wessells H, Voelzke BB. Analysis of diagnostic angiography and angioembolization in the acute management of renal trauma using a national data set. *J Urol*. 2011; 185(4): 1316-1320. doi:10.1016/j.juro.2010.12.003.
41. Glass AS, Appa AA, Kenfield SA, et al. Selective angioembolization for traumatic renal injuries: A survey on clinician practice. *World J Urol*. 2014; 32(3): 821-827. doi:10.1007/s00345-013-1169-1.
42. Serafetinides E, Kitrey ND, Djakovic N, et al. Review of the current management of upper urinary tract injuries by the EAU Trauma Guidelines Panel. *Eur Urol*. 2015; 67(5): 930-936. doi:10.1016/j.eururo.2014.12.034.
43. Bittenbinder EN, Reed AB. Advances in renal intervention for trauma. *Semin Vasc Surg*. 2013; 26(4): 165-169. doi:10.1053/j.semvascsurg.2014.06.012.
44. Beyer C, Zakaluzny S, Humphries M, Shatz D. Multidisciplinary management of blunt renal artery injury with endovascular therapy in the setting of polytrauma: A case report and review of the literature. *Ann Vasc Surg*. 2017; 38: 318.e11-318.e16. doi:10.1016/j.avsg.2016.05.130.
45. Costantini TW, Coimbra R, Holcomb JB, et al; the AAST Pelvic Fracture Study Group. Current management of hemorrhage from severe pelvic fractures: Results of an American Association for the Surgery of Trauma multi-institutional trial. *J Trauma Acute Care Surg*. 2016; 80(5): 717-723; discussion 723-725. doi:10.1097/TA.0000000000001034.
46. Cullinane DC, Schiller HJ, Zielinski MD, et al. Eastern Association for the Surgery of Trauma practice management guidelines for hemorrhage in pelvic fracture--update and systematic review. *J Trauma*. 2011; 71(6): 1850-1868. doi:10.1097/TA.0b013e31823dca9a.
47. Burlew CC, Moore EE, Smith WR, et al. Preperitoneal pelvic packing/external fixation with secondary angioembolization: Optimal care for life-threatening hemorrhage from unstable pelvic fractures. *J Am Coll Surg*. 2011; 212(4): 628-635; discussion 635-637. doi:10.1016/j.jamcollsurg.2010.12.020.
48. Chu CH, Tennakoon L, Maggio PM, Weiser TG, Spain DA, Staudenmayer KL. Trends in the management of pelvic fractures, 2008-2010. *J Surg Res*. 2016; 202(2): 335-340. doi:10.1016/j.jss.2015.12.052.
49. Schwartz DA, Medina M, Cotton BA, et al. Are we delivering two standards of care for pelvic trauma? Availability of angioembolization after hours and on weekends increases time to therapeutic intervention. *J Trauma Acute Care Surg*. 2014; 76(1): 134-139. doi:10.1097/TA.0b013e3182ab0cfc.
50. Tesoriero RB, Bruns BR, Narayan M, et al. Angiographic embolization for hemorrhage following pelvic fracture: Is it "time" for a paradigm shift? *J Trauma Acute Care Surg*. 2017; 82(1): 18-26. doi:10.1097/TA.0000000000001259.



51. Brasel KJ, Pham K, Yang H, Christensen R, Weigelt JA. Significance of contrast extravasation in patients with pelvic fracture. *J Trauma*. 2007; 62(5): 1149-1152. doi:10.1097/TA.0b013e3180479827.
52. Papakostidis C, Kanakaris N, Dimitriou R, Giannoudis PV. The role of arterial embolization in controlling pelvic fracture haemorrhage: A systematic review of the literature. *Eur J Radiol*. 2012; 81(5): 897-904. doi:10.1016/j.ejrad.2011.02.049.
53. Fang J-F, Shih L-Y, Wong Y-C, Lin B-C, Hsu Y-P. Repeat transcatheter arterial embolization for the management of pelvic arterial hemorrhage. *J Trauma*. 2009; 66(2): 429-435. doi:10.1097/TA.0b013e31817c969b.
54. Shapiro M, McDonald AA, Knight D, Johannigman JA, Cuschieri J. The role of repeat angiography in the management of pelvic fractures. *J Trauma*. 2005; 58(2): 227-231.
55. Hymel A, Asturias S, Zhao F, et al. Selective versus nonselective embolization versus no embolization in pelvic trauma: A multicenter retrospective cohort study. *J Trauma Acute Care Surg*. May 2017; 83(3): 361-367. doi:10.1097/TA.0000000000001554.
56. Auerbach AD, Rehman S, Kleiner MT. Selective transcatheter arterial embolization of the internal iliac artery does not cause gluteal necrosis in pelvic trauma patients. *J Orthop Trauma*. 2012; 26(5): 290-295. doi:10.1097/BOT.0b013e31821f9574.
57. Shi J, Gomes A, Lee E, et al. Complications after transcatheter arterial embolization for pelvic trauma: Relationship to level and laterality of embolization. *Eur J Orthop Surg Traumatol*. 2016; 26(8): 877-883. doi:10.1007/s00590-016-1832-5.
58. Matityahu A, Marmor M, Elson JK, et al. Acute complications of patients with pelvic fractures after pelvic angiographic embolization. *Clin Orthop Relat Res*. 2013; 471(9): 2906-2911. doi:10.1007/s11999-013-3119-z.
59. Gourlay D, Hoffer E, Routt M, Bulger E. Pelvic angiography for recurrent traumatic pelvic arterial hemorrhage. *J Trauma*. 2005; 59(5):1168-1174.
60. Kimbrell BJ, Velmahos GC, Chan LS, Demetriades D. Angiographic embolization for pelvic fractures in older patients. *Arch Surg*. 2004; 139(7): 728-32-discussion732-3. doi:10.1001/archsurg.139.7.728.
61. Quartey B, Jessie E. Pulmonary artery and vein pseudoaneurysm after gunshot wound to the chest. *J Emerg Trauma Shock*. 2011; 4(2): 313-316. doi:10.4103/0974-2700.82235.
62. Velez E, Surman AM, Nanavati SM, et al. CT-detected traumatic small artery extremity injuries: Surgery, embolize, or watch? A 10-year experience. *Emerg Radiol*. 2016; 23(1): 57-61. doi:10.1007/s10140-015-1366-x.
63. Yuan K-C, Hsu Y-P, Wong Y-C, Fang J-F, Lin B-C, Chen H-W. Management of complicated lumbar artery injury after blunt trauma. *Ann Emerg Med*. 2011; 58(6): 531-535. doi:10.1016/j.annemergmed.2011.07.002.



13. IMAGING IN PENETRATING NECK INJURY

Key Points

- CTA is the initial diagnostic procedure of choice in patients with penetrating neck injury who are hemodynamically stable, have an intact airway, and do not have an indication for immediate neck exploration.
- Catheter angiography may be considered when the CTA is negative, equivocal or non-diagnostic (in other words, when metallic fragments are present) in patients with a high suspicion of vascular injury.
- If aero-digestive injury is a concern despite a normal or equivocal CTA, consider a water-soluble contrast swallow, but ensure it is performed in conjunction with direct visualization techniques.

In the United States, penetrating neck injuries account for approximately 1 to 10 percent of ED trauma and have a mortality rate of up to 10 percent.^{1,2,3} The location of many vital structures in the neck increases the risk of potentially devastating injury. Approximately 15 to 25 percent of penetrating injuries to the neck result in an arterial injury. Among the penetrating arterial neck injuries, 80 percent involve the carotid arteries and up to 43 percent involve the vertebral arteries.²⁻⁴

Penetrating wounds that violated the platysma were historically divided into three anatomic zones:^{3,5}

- Zone I extends from the clavicles and sternal notch to the cricoid cartilage,
- Zone II extends from the cricoid cartilage to the mandibular angle, and
- Zone III extends from the mandibular angle to the skull base.

Traditionally, injuries to zone II were explored while injuries to zones I and III underwent additional evaluation using conventional angiography, CT, and other modalities due to the difficulty in obtaining access to injuries in these zones.^{3,5-7} With the increased use of CTA, a shift to a “no-zone” approach to the patient with penetrating neck injury has occurred.^{6,7}

Initial Evaluation

The “no-zone” approach to penetrating neck injury takes into account the clinical evaluation and the presence of hard or soft signs. See Table 8 for hard and soft signs of vascular or aero-digestive tract injury. Hard signs associated with a hemodynamically unstable or a potentially unstable patient mandate immediate operative evaluation and treatment without preoperative imaging. Hemodynamically stable patients with symptoms of cerebral ischemia or patients with soft signs of vascular and/or aero-digestive injury may benefit from imaging studies to determine the optimal surgical, endovascular, or medical therapy.



Table 8. Signs of Extremity Vascular Injury

Category	Signs
Hard signs ^{4,7,8}	Active hemorrhage Pulsatile or expanding hematoma Bruit or thrill in the region of the wound Hemodynamic instability Unilateral upper extremity pulse deficit Massive hemoptysis or hematemesis Air bubbling in the wound Airway compromise Signs of cerebral ischemia
Soft signs ^{4,7,8}	Nonpulsatile or nonexpanding hematoma Venous oozing Dysphagia Dysphonia Subcutaneous emphysema

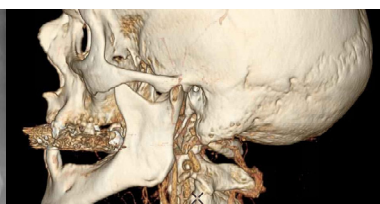
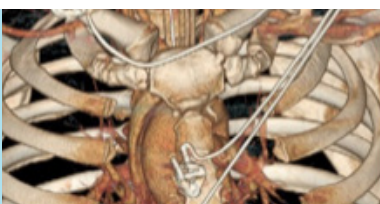
Computed Tomographic Angiography

CTA is the study of choice for patients who do not need immediate surgical intervention.⁹ CTA for evaluation of penetrating neck injury must minimally be a 16 slice MDCT. In comparison to catheter angiography, CTA is reported to have sensitivity ranging from 90 to 100 percent, with specificity ranging from 98.6 to 100 percent, a positive predictive value of 92.8 to 100 percent, and a negative predictive value of 98 to 100 percent for identification of vascular injury.^{6,9-11} The identification of extravascular soft tissue and aerodigestive injuries have a sensitivity of 100 percent and a specificity ranging from 93.5 to 97.5 percent.^{2,6-13} CT esophagography is described for diagnosing suspected upper-digestive tract injuries, but limited data exist regarding this imaging modality. In a prospective study using CT esophagography in conjunction with CTA, sensitivity was 100 versus 95 percent when CT esophagography

was performed alone. Specificity varied for both studies (CT esophagography alone or in conjunction with CTA) from 85 to 91 percent.¹⁴ Because of limited data about this novel modality, it is not considered a best practice at this time. A water-soluble contrast esophogram is considered the best practice.

The use of CTA in the initial evaluation of penetrating neck injury has reduced the number of overall neck explorations and negative neck explorations. CTA has also reduced the use of catheter angiography and esophagography.^{12,15} A recent retrospective study reported that 74 percent of patients who had hard signs, were hemodynamically stable, and had an intact airway were able to avoid neck exploration.¹⁵

CTA has replaced catheter angiography, previously considered the best practice for evaluation of penetrating neck injuries in zones I and III. However, catheter angiography can be used when CTA is equivocal or when



endovascular treatment may potentially be indicated.^{2,7,8,16,17} It is also useful when CTA is limited by streak artifact from the presence of metallic foreign bodies. In this case, digital-subtraction catheter angiography is often more sensitive for vascular evaluation.^{16,17}

Other Imaging Modalities

The use of ultrasound is often limited in penetrating neck injury. Findings can be confounded by adjacent soft tissue injury or the presence of dressings. Zones I and III are not amenable to ultrasound evaluation.^{5, 11,18-21} Studies comparing ultrasound to catheter angiography demonstrated a sensitivity of 91 percent, a specificity of 98 to 100 percent, a positive predictive value of 100 percent, and a negative predictive value of 99 percent for patients with clinical soft signs.^{20,21}

MRI/MRA has limited use in the initial evaluation of penetrating neck injury because of the potential presence of metallic foreign objects, prolonged scan time, and the potential for clinical deterioration.^{5,9,19} It is valuable in the evaluation of spinal cord injury, traumatic disc injury, ligamentous neck injury, blood within the spinal canal, and laryngeal cartilaginous injuries.^{4,22}

The role of upper gastrointestinal tract imaging is generally confined to evaluating potential esophageal injuries. Oropharyngeal and hypopharyngeal injuries are typically not seen on contrast fluoroscopic studies.²³ When esophageal injury is suspected, water-soluble contrast is preferred due to the risk of extraluminal contrast

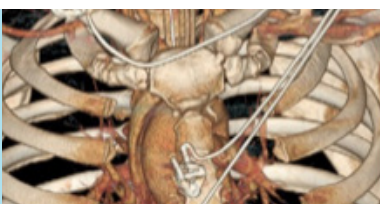
extravasation.⁹ Panendoscopy with laryngoscopy, bronchoscopy and esophagoscopy (flexible and rigid) is the gold standard for evaluation of oropharyngeal, hypopharyngeal, laryngotracheal, and esophageal injuries.⁹

References

1. O'Brien PJ, Cox MW. A modern approach to cervical vascular trauma. *Perspect Vasc Surg Endovasc Ther.* 2011; 23(2): 90-97.
2. Saito N, Hito R, Burke PA, Sakai O. Imaging of penetrating injuries of the head and neck: Current practice at a level I trauma center in the United States. *Keio J Med.* 2014; 63(2): 23-33.
3. Steenburg SD, Sliker CW, Shanmuganathan K, Siegel EL. Imaging evaluation of penetrating neck injuries. *RadioGraphics.* 2010; 30(4): 869-886.
4. Stallmeyer MJ, Morales RE, Flanders AE. Imaging of traumatic neurovascular injury. *Radiol Clin North Am.* 2006; 44(1): 13-39, vii.
5. Low GM, Inaba K, Chouliaras K, et al. The use of the anatomic 'zones' of the neck in the assessment of penetrating neck injury. *Am Surg.* 2014; 80(10): 970-974.
6. Inaba K, Branco BC, Menaker J, et al. Evaluation of multidetector computed tomography for penetrating neck injury: A prospective multicenter study. *J Trauma Acute Care Surg.* 2012; 72(3): 576-583; discussion 583-574; quiz 803-574.
7. Shiroff AM, Gale SC, Martin ND, et al. Penetrating neck trauma: A review of management strategies and discussion of the 'No Zone' approach. *Am Surg.* 2013; 79(1): 23-29.
8. Sperry JL, Moore EE, Coimbra R, et al. Western Trauma Association critical decisions in trauma: Penetrating neck trauma. *J Trauma Acute Care Surg.* 2013; 75(6): 936-940.
9. Expert Panels on Neurologic and Vascular Imaging: Schroeder JW, Ptak T, Corey AS, et al. ACR Appropriateness Criteria[®] penetrating neck injury. *J Am Coll Radiol.* 2017 Nov; 14(11S): S500-505.
10. Brywczyński JJ, Barrett TW, Lyon JA, Cotton BA. Management of penetrating neck injury in the emergency department: A structured literature review. *Emerg Med J.* 2008; 25(11): 711-715.
11. Patterson BO, Holt PJ, Cleanthis M, Tai N, Carrell T, Loosemore TM. Imaging vascular trauma. *Br J Surg.* 2012; 99(4): 494-505.



12. Woo K, Magner DP, Wilson MT, Margulies DR. CT angiography in penetrating neck trauma reduces the need for operative neck exploration. *Am Surg.* 2005; 71(9): 754-758.
13. Bodanapally UK, Shanmuganathan K, Dreizin D, et al. Penetrating aerodigestive injuries in the neck: A proposed CT- aided modified selective management algorithm. *Eur Radiol.* 2016; 26(7): 2409-2417.
14. Conradie WJ, Gebremariam FA. Can computed tomography esophagography reliably diagnose traumatic penetrating upper digestive tract injuries? *Clin Imaging.* 2015; 39(6): 1039-1045.
15. Schroll R, Fontenot T, Lipcsey M, et al. Role of computed tomography angiography in the management of Zone II penetrating neck trauma in patients with clinical hard signs. *J Trauma Acute Care Surg.* 2015; 79(6): 943-950; discussion 950.
16. Cox MW, Whittaker DR, Martinez C, Fox CJ, Feuerstein IM, Gillespie DL. Traumatic pseudoaneurysms of the head and neck: Early endovascular intervention. *J Vasc Surg.* 2007; 46(6): 1227-1233.
17. Greer LT, Kuehn RB, Gillespie DL, et al. Contemporary management of combat-related vertebral artery injuries. *J Trauma Acute Care Surg.* 2013; 74(3): 818-824.
18. Fox CJ, Gillespie DL, Weber MA, et al. Delayed evaluation of combat-related penetrating neck trauma. *J Vasc Surg.* 2006; 44(1): 86-93.
19. Schroeder JW, Baskaran V, Aygun N. Imaging of traumatic arterial injuries in the neck with an emphasis on CTA. *Emerg Radiol.* 2010; 17(2): 109-122.
20. Demetriades D, Theodorou D, Cornwell E, et al. Evaluation of penetrating injuries of the neck: Prospective study of 223 patients. *World J Surg.* 1997; 21(1): 41-47; discussion 47-48.
21. Demetriades D, Theodorou D, Cornwell E, 3rd, et al. Penetrating injuries of the neck in patients in stable condition. Physical examination, angiography, or color flow Doppler imaging. *Arch Surg.* 1995; 130(9): 971-975.
22. Becker M, Leuchter I, Platon A, Becker CD, Dulguerov P, Varoquaux A. Imaging of laryngeal trauma. *Eur J Radiol.* 2014; 83(1): 142-154.
23. Ahmed N, Massier C, Tassie J, Whalen J, Chung R. Diagnosis of penetrating injuries of the pharynx and esophagus in the severely injured patient. *J Trauma.* 2009; 67(1): 152-154.



14. IMAGING IN PENETRATING TRANSTHORACIC TRAUMA

Key Points

- The role of imaging to evaluate patients with penetrating transthoracic trauma is determined by hemodynamic stability, mechanism of injury, and location of injury.
- Penetrating injuries to the chest between the nipple lines anteriorly or the scapula posteriorly have the potential to injure the heart or great vessels.
- Most injuries are to the lungs and pleura and may be evaluated with serial radiographs. Contrast-enhanced MDCT is used with increasing frequency in patients with hemodynamic stability.
- Penetrating injuries entering below the tip of the scapula posteriorly or the inframammary crease anteriorly have the potential to traverse the diaphragm and cause abdominal injury.

Penetrating thoracic trauma injury mechanisms include stab, puncture, and high- and low-velocity gunshot wounds. Penetrating chest injuries account for 1 to 13 percent of trauma admissions and acute exploration is required in 5 to 15 percent of cases; exploration is required in 15 to 30 percent of patients who are

unstable or when active hemorrhage is suspected.¹⁻⁴ The role of imaging in these patients depends on three interrelated factors: patient stability, injury mechanism, and location of the wounds. When a patient is stable different diagnostic and therapeutic options can be considered. The approach to imaging for the unstable patient is predicated on getting to the OR as soon as possible with minimal delay for extraneous testing.

Cardiac Box Injuries

Penetrating thoracic trauma encompasses a heterogeneous group of injuries with differing presentations. Penetrating injuries to the chest between the nipple lines anteriorly or the scapula posteriorly, referred to as the “cardiac box,” have the potential for cardiac or great vessel injury.^{5,6} The cardiac box may also be violated when the external wounds are not within the described classic borders because the patient’s body is in a different position at the time of injury. Injuries below the level of the tip of the scapula posteriorly or the inframammary crease/nipple anteriorly have the potential to traverse the diaphragm, particularly left lower thoracic injuries.¹ Up to 20 percent of patients with penetrating injuries have associated abdominal injuries.⁷ (See Imaging in Penetrating Abdominal Trauma section.)

When an injury path traverses the cardiac box be concerned about a potential cardiac injury. Imaging evaluation of patients with suspected cardiac injury depends on the patient’s hemodynamic stability. Immediate surgical intervention is the only meaningful treatment of



unstable patients with penetrating cardiac injury. The cardiac view of FAST is widely used to evaluate for traumatic hemopericardium, and it has supplanted the diagnostic pericardial window.⁸ For the stable patient with a penetrating injury to the cardiac box perform a chest radiograph to identify potential retained foreign bodies and the potential ballistic trajectory. Perform FAST to evaluate for hemopericardium. A positive FAST leads to emergent surgical intervention. When the FAST is negative, consider contrast-enhanced MDCT scan (optimally at least a 64 slice) to further delineate the injury trajectory.⁹ Note that the FAST may be negative for pericardial fluid in patients with hemothorax as the cardiac injury may decompress into the chest.

Lateral Hemithorax Injuries

Penetrating injuries to the lateral hemithorax raise concern for injuries to the chest wall and lung parenchyma. When the patient is unstable with absent breath sounds, indicative of pneumothorax and/or hemothorax, place chest tubes on the affected side without waiting for confirmatory imaging. Point-of-care chest ultrasonography (extended Focused Assessment with Sonography in Trauma [eFAST]) can be used to document pneumothorax/hemothorax when the provider has adequate training.¹⁰ Clinical examination for hemothorax and/or pneumothorax can be incorrect in up to a third of cases.¹¹

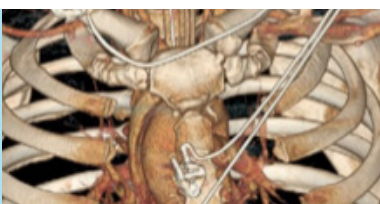
Initially image the patient who is hemodynamically stable with chest radiography.^{11,12} Delineate wounds with radiopaque markers to help

approximate the injury trajectory. If the patient with penetrating non-mediastinal thoracic trauma has a normal initial chest radiograph, perform a follow up chest radiograph in 3-6 hours to rule out development of a delayed pneumothorax. Trauma centers with expertise in ultrasonography may choose to use this technique as a screening tool to detect pneumothorax and/or hemothorax.^{11,12}

In hemodynamically stable patients obtain a chest radiograph to evaluate for the presence of a hemothorax or pneumothorax before performing tube drainage. Perform a repeat chest radiograph after chest drainage to assess for retained hemothorax and/or pneumothorax. Consider using a contrast-enhanced MDCT scan (optimally at least a 64 slice) for patients with penetrating injuries to the lateral hemithorax to evaluate for active chest wall hemorrhage, residual hemothorax and/or pneumothorax.

Transmediastinal Penetrating Injury

Transmediastinal penetrating injury is defined as penetrating injury that traverses any part of the mediastinum and can involve any of its sensitive structures, including the heart, great vessels, trachea and bronchi, and the esophagus. Transmediastinal injury can be inferred from wounds on opposite sides of the thorax, an entry site and main ballistic mass on opposite sides of the thorax, or a main ballistic mass projecting over the mediastinum.

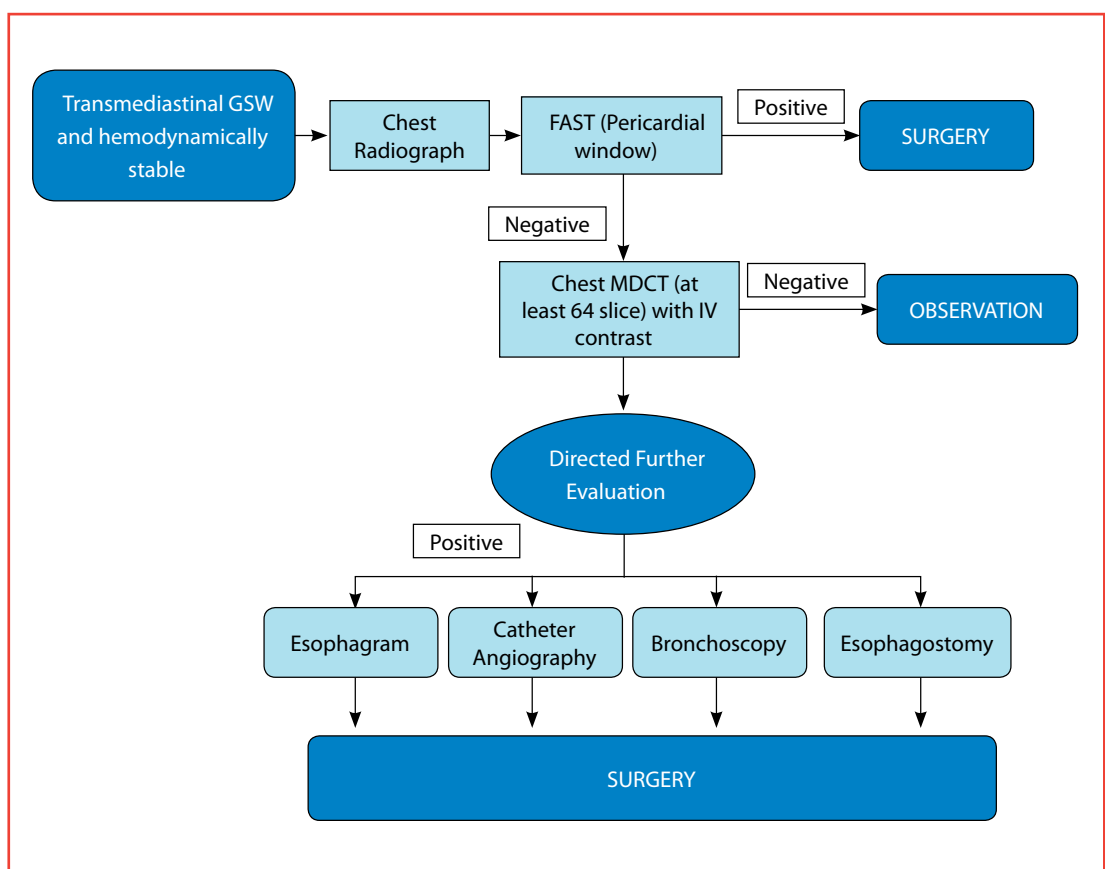


Imaging evaluation of patients with suspected mediastinal injury depends on the patient's stability.

For the patient who is hemodynamically unstable perform emergent surgical intervention without any imaging at admission. If time and hemodynamics permit, imaging with an initial chest radiograph, eFAST (for those trained), or limited pericardial ultrasound is the possible exception.

In the past, hemodynamically stable patients with, transmediastinal injury were evaluated by any combination of conventional angiography, bronchoscopy, esophagoscopy, esophagram, transthoracic or transesophageal echocardiography, pericardial window, or pericardiocentesis.¹³ With advances in imaging, the approach to transmediastinal penetrating injuries is streamlined and limits invasive studies. FAST is used initially to evaluate for pericardial fluid, and a

Figure 6. Diagnostic Algorithm for Transmediastinal GSW¹³



Source: Gunn ML, Clark RT, Sadro CT, Linnau KF, Sandstrom CK. Current concepts on imaging evaluation of penetrating transmediastinal injury. *RadioGraphics*. 2014; 34(7): 1824-1941; Burack JH, Kandil E, Sawas A, et al. Triage and outcome of patients with mediastinal penetrating trauma. *Ann Thorac Surg*. 2007; 83: 377-382; Karmy-Jones R, Namias N, Coimbra R, et al. Western Trauma Association Critical Decisions in Trauma: Penetrating chest trauma. *J Trauma Acute Care Surg*. 2014; 77(6): 994-2003; Stassen NA, Lukan JK, Spain DA, et al. Reevaluation of diagnostic procedures for transmediastinal gunshot wounds. *J Trauma*. 2002; 53(4): 635-638; and Remz FM, Cava RA, Feliciano DV, Rozycki GS. Transmediastinal gunshot wounds: A prospective study. *J Trauma*. 2000. 48(3): 416-421.



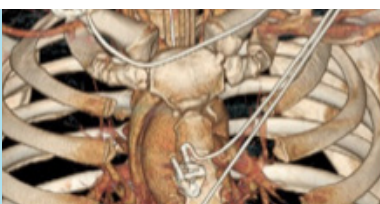
contrast-enhanced MDCT scan (optimally at least a 64 slice) is used to screen for proximity to aero-digestive and major vascular structures.¹³ Patients with negative cardiac ultrasound and contrast-enhanced MDCT scan can be safely observed, and patients with positive results are referred for further evaluation as delineated in Figure 6. If there is concern for aero-digestive injuries on CT, then further evaluation may include an esophogram with water-soluble contrast along with direct visualization via endoscopy and bronchoscopy.

Potential for Abdominal Injury

Penetrating transthoracic injury below the tip of the scapula posteriorly or the inframammary crease anteriorly has the potential to traverse the diaphragm; consider imaging of the abdomen in these patients (See the Penetrating Abdominal Trauma section). Perform a chest radiograph as the initial imaging study to evaluate for diaphragmatic injury. The sensitivity of diagnosing a diaphragmatic injury on chest radiograph is 24 to 50 percent. If the chest radiograph is inconclusive and the patient remains stable, perform a contrast-enhanced MDCT scan (optimally at least a 64 slice) with coronal reconstructions to evaluate for potential diaphragmatic injury. Although the sensitivity of a contrast-enhanced MDCT scan in diagnosing diaphragmatic injury is higher than chest radiograph, consider further intervention with thoracoscopy or laparoscopy if the MDCT findings are not conclusive.^{14,15}

References

1. Calhoun JH, Trinkle JK. Pathophysiology of chest trauma. *Chest Surg Clin N Am.* 1997; 7(2): 199-211.
2. Karmy-Jones R, Jurkovich GJ, Shatz DV, et al. Management of traumatic lung injury: A Western Trauma Association multicenter review. *J Trauma.* 2001; 51(6): 1049-1053.
3. Thompson DA, Rowlands BJ, Walker WE, Kuykendall RC, Miller PW, Fischer RP. Urgent thoracotomy for pulmonary or tracheobronchial injury. *J Trauma.* 1988; 28: 276-280.
4. Robison PD, Harman PK, Trinkle JK, Grover FL. Management of penetrating lung injuries in civilian practice. *J Thorac Cardiovasc Surg.* 1988; 95(2): 184-90.
5. Siemens R, Polk HC Jr, Gray LA Jr, Fulton RL. Indications for thoracotomy following penetrating thoracic injury. *J Trauma.* 1977; 17(7): 493-500.
6. Brown J, Grover FL. Trauma to the heart. *Chest Surg Clin N Am.* 1997; 7(2): 325-341.
7. Renz BM, Cava RA, Feliciano DV, Rozycki GS. Transmediastinal gunshot wounds: A prospective study. *J Trauma.* 2000; 48(3): 416-421; discussion 421-422.
8. Dulchavsky SA, Schwarz KL, Kirkpatrick AW, et al. Prospective evaluation of thoracic ultrasound in the detection of pneumothorax. *J Trauma.* 2001; 50(2): 201-205.
9. LeBlang SD, Dolich MO, Matthew O. Imaging of penetrating thoracic trauma. *J Thorac Imaging.* 2000; 15(2): 128-135.
10. deVries CS, Africa M, Gebremariam FA, van Rensburg JJ, Otto SF, Potgieter HF. The imaging of stab injuries. *Acta Radiol.* 2010; 51(1): 92-106.
11. Kang N, Hsee L, Rizoli S, Alison P. Penetrating cardiac injury: Overcoming the limits set by Nature. *Injury.* 2009; 40(9): 919-927.
12. Plurad DS, Bricker S, Van Natta TL, et al. Penetrating cardiac injury and the significance of chest computed tomography findings. *Emerg Radiol.* 2013; 20(4): 279-284.
13. Stassen NA, Lukan JK, Spain DA, et al. Reevaluation of diagnostic procedures for transmediastinal gunshot wounds. *J Trauma.* 2002; 53(4): 635-638.
14. Murray JA, Demetriades D, Cornwell EE 3rd, et al. Penetrating left thoracoabdominal trauma: The incidence and clinical presentation of diaphragm injuries. *J Trauma.* 1997; 43(4): 624-626.
15. Rodriguez-Morales G, Rodriguez A, Shatney CH. Acute rupture of the diaphragm in blunt trauma: Analysis of 60 patients. *J Trauma.* 1986; 26(5): 438-444.



15. IMAGING IN PENETRATING ABDOMINAL TRAUMA

Key Points

- Do not delay operative management to image patients with peritonitis, hypotension, evisceration, or frank gastrointestinal bleeding.
- Consider using eFAST for the initial evaluation of stable and unstable patients with projectile injuries to evaluate the pericardium for fluid and tamponade.
- Radiographs can be useful to identify the course or location of a projectile, but have little use in management of stab wounds.
- MDCT for penetrating trauma plays a key role in selective nonoperative management and evaluation of back or flank wounds.

The role, and type of imaging, in penetrating abdominal trauma depends on several factors such as anatomic location of injury, injury type, and stability of the patient. Consider immediate laparotomy for patients with hemodynamic instability, hypotension, peritonitis, impalement, or evisceration. Imaging can be useful in guiding management for stable patients without these findings.

It is useful to think of the abdomen in terms of specific anatomic areas at risk from penetrating injury.

- The anterior abdomen extends from the 4th intercostal space (approximately the nipple line in men or inframammary crease in women) to the inguinal ligaments and the midaxillary lines laterally.
- The flank is the area between the anterior and posterior axillary lines and the iliac crest and costal margin.
- The back is between the scapula tip and the iliac crests and the posterior axillary lines.

Penetrating injuries to any of these areas put the abdomen and retroperitoneum at risk. Injuries at the cephalad or caudal extremes of these areas can also injure the chest or pelvis respectively.

Imaging Firearm Injuries

Do not delay operative management to image patients with peritonitis, hypotension, evisceration, or frank gastrointestinal bleeding. Proceed to laparotomy. However, limited imaging may be useful in some cases. In addition to the location of injury, the type of injury (for example, ballistic or gunshot wounds) also influences imaging. Shotguns often use pellets or multiple projectiles, and their injury patterns differ from other firearm injuries. Pellets spread out and slow down quickly. Often multiple projectiles are spread over a large area. While the indications for emergent operation remain the same, plain radiographs can help determine if multiple body cavities are involved. In stable patients, CT can help determine the extent of injury and guide exploration.



Some high-volume trauma centers now practice selective nonoperative management of abdominal firearm wounds for patients who do not meet these criteria with the use of MDCT scanners.^{1,2} It is recommended that trauma centers develop a standardized approach to imaging in these patients coupled with a robust performance improvement practice.

Ultrasound

Bedside ultrasound, such as the eFAST, can be used in the initial evaluation of stable and unstable patients with projectile injuries to evaluate the pericardium for fluid and identify possible tamponade.³ This information can be important for identifying treatment priorities.⁴ It is important to distinguish between blood and the epicardial fat pads. Movement of the epicardial fat pads with the heart is a critical distinguishing feature. With penetrating injuries it is also possible to have false negatives due to blood decompressing out of the pericardium into the hemithorax. Ultrasound can also identify intraabdominal fluid, however, it cannot discern specific injuries. In penetrating trauma, the sensitivity of ultrasound for intraabdominal fluid may be as low as 43 percent. Ultrasound cannot rule out abdominal injury of the abdomen, and it often does not change acute management.

Radiographs

Radiographs can be useful to identify the course or location of the projectile. They do not, however, definitively rule out violation of the peritoneum. If more

specific information regarding the location of the projectile on radiograph imaging is desired, obtain films in two dimensions. This is not routinely performed, and do not delay operative or other diagnostic and therapeutic interventions to obtain additional films. Abdominal radiograph including the pelvis for penetrating abdominal injuries may be useful to locate foreign bodies. Obtain chest radiographs in patients with a cephalad abdominal injury or lower chest injury. Mark surface wounds prior to image acquisition. Marking can be helpful when the projectile has exited the patient, but it will be less helpful in the case of multiple gunshot injuries.^{5,6}

Computed Tomography

In stable patients with a projectile injury and no indication for laparotomy, obtain a MDCT scan of the abdomen with IV contrast (See CT section under stab wounds).^{7,8} The addition of oral and rectal contrast may be used for these evaluations; however, current data do not suggest that the addition of oral and rectal contrast is superior to IV contrast alone.^{9,10} It is recommended that trauma centers have imaging protocols in place to guide the use of contrast, and to track results as part of a PI program. MDCT can distinguish if the projectile entered the peritoneal cavity.^{11,12} If the injury is in the flank or back, the likelihood of injury to retroperitoneal structures is increased. MDCT also has the ability detect direct organ injury, such as hepatic lacerations. In some trauma centers, operative management may not be the initial treatment in such cases.² MDCT may also be a useful adjunct following



operative exploration, such as when spine imaging is needed, or to assess for a missed injury after damage control.^{13,14}

Imaging Stab Wounds

Stab wounds differ from ballistic injury in amount of energy that is transferred to the tissues. Imaging may not be able to detect the path of the penetrating object, particularly when the object is no longer present. In patients with obvious internal injury, do not delay surgical exploration to obtain imaging. However, imaging does play a role in guiding stab wound management.

Ultrasound

Bedside ultrasound, such as the extended FAST (eFAST), can evaluate the pericardium for blood or the presence of tamponade.³ Ultrasound for stab wounds has the same limitations and applications as for ballistic injury.⁴ Ultrasound cannot exclude intraabdominal injury, and a negative ultrasound must be followed up with other diagnostic measures.

Radiographs

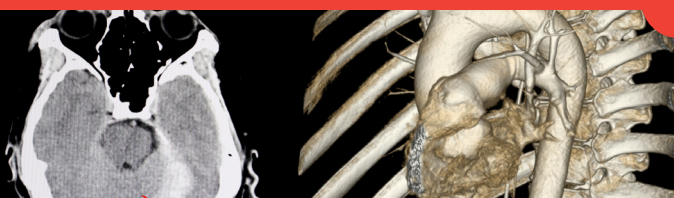Radiographs have little role in the management of abdominal stab wounds. Free air in the abdomen on upright or decubitus images indicates peritoneal violation, but not hollow-viscus injury. Radiographs may be useful in cases of impalement or suspicion of a retained foreign body. Marking the site of penetrating wounds can be useful if radiographs are taken.^{5,6}

Computed Tomography

MDCT scanners provide images with improved sensitivity and specificity in penetrating trauma.^{15,16} Detection of peritoneal violation has a reported sensitivity of 97 percent and specificity of 98 percent. However, for the detection of low-velocity penetrating injuries that produce small defects, CT relies on identification of herniation or contrast on either side of the diaphragm, or contrast extravasation from bowel to diagnose injury. This can result in missed injury. Therefore, CT plays less of a role in anterior abdominal stab wounds where local wound exploration or laparoscopy can determine penetration of the fascia.¹⁵ MDCT does have the advantage over ultrasound for evaluation of the retroperitoneum. Observe or evaluate stable patients with a negative CT scan by other means, based on facility protocols.

Increased risk to the retroperitoneal organs occurs with injuries to the back or flank, in particular, the retroperitoneal colon. For stable patients with such injuries, perform a MDCT with intraluminal contrast.^{10,17,18} Classically, this was a “triple contrast” CT with oral, rectal, and IV contrast administered. More recently it is suggested that only rectal and IV contrast may be necessary.

CT scanning protocols vary by the scanner used. For rectal contrast, flood the colon with 800-1000 mL of diluted contrast via soft rectal tube under gravity pressure only. If oral contrast is used instill diluted contrast as follows:



- By mouth: The patient drinks 300 mL of contrast prior to scan. Scan as soon as the 300 mL is given; do not wait for contrast to extend through the small bowel.
- By NG tube: 300 mL is administered through the NG tube. Scan as soon as 300 mL has been administered; do not wait for contrast to extend through small bowel.

References

1. Velmahos GC, Constantinou C, Tillou A, Brown CV, Salim A, Demetriades D. Abdominal computed tomographic scan for patients with gunshot wounds to the abdomen selected for nonoperative management. *J Trauma*. 2005; 59(5): 1155–60–discussion1160–1.
2. Demetriades D, Hadjizacharia P, Constantinou C, et al. Selective nonoperative management of penetrating abdominal solid organ injuries. *Ann Surg*. 2006; 244(4): 620–628. doi:10.1097/01.sla.0000237743.22633.01.
3. Matsushima K, Khor D, Berona K, et al. Double jeopardy in penetrating trauma: Get FAST, get it right. *World J Surg*. 2017; 39: 225. doi:10.1007/s00268-017-4162-9.
4. Boulanger BR, Kearney PA, Tsuei B, Ochoa JB. The routine use of sonography in penetrating torso injury is beneficial. *J Trauma*. 2001; 51(2): 320–325.
5. Peterson B, Shapiro MB, Crandall M, Skinner R, West MA. Trauma clip-art: Early experience with an improved radiopaque marker system for delineating the path of penetrating injuries. *J Trauma*. 2005; 58(5): 1078–1081.
6. Brooks A, Bowley DMG, Boffard KD. Bullet markers--a simple technique to assist in the evaluation of penetrating trauma. *J R Army Med Corps*. 2002; 148(3): 259–261.
7. Goodman CS, Hur JY, Adajar MA, Coulam CH. How well does CT predict the need for laparotomy in hemodynamically stable patients with penetrating abdominal injury? A review and meta-analysis. *AJR Am J Roentgenol*. 2009; 193(2): 432–437. doi:10.2214/AJR.08.1927.
8. Melo ELA, de Menezes MR, Cerri GG. Abdominal gunshot wounds: Multi-detector-row CT findings compared with laparotomy: A prospective study. *Emerg Radiol*. 2012; 19(1): 35–41. doi:10.1007/s10140-011-1004-1.
9. Ramirez RM, Cureton EL, Ereso AQ, et al. Single-contrast computed tomography for the triage of patients with penetrating torso trauma. *J Trauma*. 2009; 67(3): 583–588. doi:10.1097/TA.0b013e3181a39330.
10. Saksobhavit N, Shanmuganathan K, Boscak AR, et al. Diagnostic accuracy of triple-contrast multi-detector computed tomography for detection of penetrating gastrointestinal injury: A prospective study. *Eur Radiol*. 2016; 26(11): 4107–4120. doi:10.1007/s00330-016-4260-3.
11. Shanmuganathan K, Mirvis SE, Chiu WC, Killeen KL, Hogan GJF, Scalea TM. Penetrating torso trauma: Triple-contrast helical CT in peritoneal violation and organ injury--A prospective study in 200 patients. *Radiology*. 2004; 231(3): 775–784. doi:10.1148/radiol.2313030126.
12. Chiu WC, Shanmuganathan K, Mirvis SE, Scalea TM. Determining the need for laparotomy in penetrating torso trauma: A prospective study using triple-contrast enhanced abdominopelvic computed tomography. *J Trauma*. 2001; 51(5): 860–8–discussion868–9.
13. Haste AK, Brewer BL, Steenburg SD. Diagnostic yield and clinical utility of abdominopelvic CT following emergent laparotomy for trauma. *Radiology*. 2016; 280(3): 735–742. doi:10.1148/radiol.2016151946.
14. Matsushima K, Inaba K, Dollbaum R, et al. The role of computed tomography after emergent trauma operation. *J Surg Res*. 2016; 206(2): 286–291. doi:10.1016/j.jss.2016.08.033.
15. Salim A, Sangthong B, Martin M, et al. Use of computed tomography in anterior abdominal stab wounds: Results of a prospective study. *Arch Surg*. 2006; 141(8): 745–50–discussion750–2. doi:10.1001/archsurg.141.8.745.
16. Uzunosmanoğlu H, Çorbacioğlu ŞK, Çevik Y, et al. What is the diagnostic value of computed tomography tractography in patients with abdominal stab wounds? *Eur J Trauma Emerg Surg*. 2017; 43(2): 273–277. doi:10.1007/s00068-015-0625-6.
17. Pham TN, Heinberg E, Cuschieri J, et al. The evolution of the diagnostic work-up for stab wounds to the back and flank. *Injury*. 2009; 40(1): 48–53. doi:10.1016/j.injury.2008.09.014.
18. Bansal V, Reid CM, Fortlage D, et al. Determining injuries from posterior and flank stab wounds using computed tomography tractography. *Am Surg*. 2014; 80(4): 403–407.



16. IMAGING IN THE TRAUMA PATIENT WHO IS MORBIDLY OBESE

Key Points

- Obesity compromises the clinical examination and all imaging modalities.
- CT remains the mainstay for diagnostic imaging in trauma patients with morbid obesity.
- If the facility's capability to image is inadequate, imaging outsourcing or transfer of care may be required.
- Facilities treating trauma patients must know the weight and size limits of their radiologic equipment.
- Regularly review and update radiologic technology to minimize the impact on care to patients with obesity.

The "epidemic" of obesity is more prevalent in the United States than other high-income countries, having the highest mean body mass index (BMI). One in 3 adults in the United States is obese (BMI of 30 kg/m² or higher).¹ Additionally, nearly 7 percent of the United States population is morbidly obese (BMI greater than 40 kg/m²).² National trauma registries now reflect an increasing prevalence of morbidly obese patients in trauma populations. Obesity compromises the clinical examination and all imaging modalities used for injury diagnosis.

Ultrasound

FAST is a routine and critical part of the initial evaluation of all trauma patients. The increased depth of subcutaneous fat and its sound-attenuating characteristics in obese patients present a significant challenge in obtaining diagnostic FAST imaging.³⁻⁵ Use of lower frequency probes facilitate tissue penetration, and therefore better identification of deep structures, but it also contributes to lower resolution imaging. The propensity toward blunt chest injuries in this population can also complicate image acquisition when extra-thoracic air is present.

CT imaging remains the best alternative in patients who are hemodynamically stable, particularly when FAST is compromised by the effects of morbid obesity. Conventional radiographs, diagnostic peritoneal lavage, laparoscopy, or exploratory laparotomy are all viable alternatives in unstable patients where FAST image quality is insufficient to guide clinical decision-making.

Radiographs

Obesity adversely affects conventional radiography with the increased body mass and the distance photons must pass in order to generate images. Resulting beam attenuation and background scatter lowers image contrast. While this effect can be mitigated through longer exposure time, it allows the opportunity for more motion artifact. Increasing energy delivery by modulating kVp or mAs and using appropriate collimation can decrease scatter and improve image quality.⁵ It is not possible to completely compensate



for all of these factors, and the overall net effect is reduced sensitivity of conventional radiographic imaging in obese trauma patients. In penetrating injuries, trajectory determination is complicated by the need to obtain multiple exposures to include all the peripheral subcutaneous tissue when surveying for retained foreign bodies.

Newer portable radiograph units common to trauma bays have generators with capacities similar to fixed units, and they can achieve adequate imaging for most patients. However, older generation portable radiograph units may produce images of insufficient quality to guide treatment. In such situations patients may require transport to fixed units in the Radiology Suite with better capability. Increased energy utilization and longer exposure times required for imaging obese patients inevitably results in higher overall radiation exposures when compared with their non-obese counterparts. Nonetheless, the overall exposure remains low when compared with CT.

Computed Tomography

CT imaging remains far superior in sensitivity for both bony and soft tissue injury compared to radiographs in the morbidly obese population. However, increasing BMI still has potential to compromise quality image acquisition in several important respects. A major barrier to CT imaging in this population can be table load and aperture limits of the gantry. A 2008 national survey of hospitals with EDs revealed only 10 to 28 percent of hospitals were

equipped with CT scanners designed to accommodate bariatric patients.⁶ CT scanners appropriate for use by morbidly obese patients tolerate high table loads (up to 680 lbs), have wide gantry apertures (85-90 cm), larger scan fields of view (65-85 cm), more powerful generators (tube voltage of 140 kVp), and iterative reconstruction options that improve image quality by reducing noise without limiting resolution.⁷ Older generation scanners may have significantly lower capacity limits, and frequently lack extended field of view. Patients presenting with size or weight exceeding the capacity of the presenting facility's scanner may require alternative diagnostic regimens or transfer to a facility with enhanced imaging capability. It is important for each facility to continually re-evaluate its imaging capability to ensure it is compatible with the facility's goals of trauma care. All facilities need a plan for outsourcing of CT imaging or transfer of care when necessary.

In addition to physical limits of the facility's scanner, overall resolution of CT is compromised for morbidly obese patients by artifacts unique to this population. The multiple artifacts induced by imaging the obese population are beyond the scope of this publication. However, MDCT scanners manufactured after 2012 are able to compensate for common artifacts through software enhancements, larger fields of view, and improved power capabilities. Obese habitus and physiology are especially challenging when vascular enhancement is required.



Compromised cardiac output and alteration of intravascular volume are frequent in obese patients, and they adversely affect contrast dynamics. The net effect is a need for higher absolute doses of contrast and higher flow rates to obtain adequate vascular and parenchymal opacification. Utilization of a proximal (antecubital) peripheral large bore (18 gauge or higher) or central venous catheter is recommended.⁷ Insufficient vascular access is a frequent source of delay for these studies. On occasion, maximal dose recommendations for contrast may exceed standard recommendations to obtain sufficient image quality as to be diagnostic. Bolus trigger and bolus tracking software are critical to the optimal timing of injection. Despite the above challenges, the overall high sensitivity of CT imaging, along with its immediate availability in most centers continue to make CT the imaging modality of choice in trauma patients who are obese and hemodynamically stable.

MRI

Many of the same physical table and aperture limitations encountered in CT imaging are also relevant to MRI. Most scanners of 1.5 tesla (T) and higher only accommodate patients weighing less than 350 lb (159 kg) or with girths less than 60 cm. However, some magnets with larger bores (70 cm) and higher table weight limits (500 lb) are now available. Vertical field open MRI systems can be used in patients up to 550 lb (250 kg) and have apertures up to 55 cm, but they have lower signal-to-noise ratios

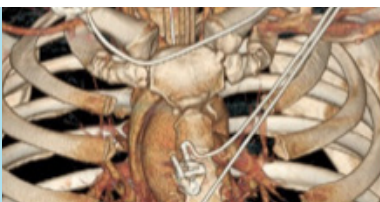
and weaker gradients that can affect image quality.⁸ Bore length in cylindrical scanners often produces claustrophobic symptoms in obese patients also limiting its use. Obese patients require a larger field of view that degrades image quality as the field enlarges. One strategy to deal with this problem is to cone the field of view down to the organ or structure of interest, whenever feasible. In addition, obese patients are at increased risk for radiofrequency energy induced tissue injury if skin and subcutaneous tissues are allowed to abut the scanner gantry. Issues with image quality, as well as safety risks associated with sedation, transport, and image acquisition continue to limit the applicability of MRI for most obese patients in the acute trauma setting.

References

1. Funucane MM, Stevens GA, Cowan MJ, et al. National, regional and global trends in body-mass index since 1980: Systemic analysis of health examination surveys and epidemiological studies with 960 country-years and 9.1 million participants. *Lancet*. 2011; 377(9765): 557-567.
2. Sturm R, Hattori A. Morbid obesity rates continue to rise rapidly in the US. *Int J Obes (Lond)*. 2013 June; 37(6): 889-891. Doi:10.1038/ijo.2012.159.
3. Rawwan MM, Abu-Zidan FM. Focused assessment sonography for trauma (FAST) and CT scan in blunt abdominal trauma: Surgeon's perspective. *Afr Health Sci*. 2006; 6(3): 187-90.
4. Bushberg JT, Seibert JA, Leidholdt EM, Boone JM. *The essential physics of medical imaging*. 3rd Ed. Philadelphia, PA: Lippincott Williams & Wilkins; 2012.
5. Uppot RN, Sahani DV, Hahn PF, Gervais D, Mueller P. Impact of obesity on medical imaging and image-guided intervention. *Am J Roentgenol*. 2007; 188(2): 433-440.



6. Ginde AA, Foianini A, Renner DM, Valley M, Camargo CA Jr. The challenge of CT and MRI imaging of obese individuals who present to the emergency department: A national survey. *Obesity* (Silver Spring). 2008; 16(11): 2549-2551.
7. Fursevich DM, Limarzi GM, O'Dell MC, Hernandez MA, Sensakovic WF. Bariatric CT Imaging: Challenges and solutions. *RadioGraphics*. 2016; 36: 1076-1086.
8. Uppot R, Sheehan A, Seethamraju R. *MRI hot topic: Obesity and MR imaging*. Malvern, PA: Siemens Medical Solutions; 2005.



17. IMAGING IN THE TRAUMA PATIENT WHO IS PREGNANT

Key Points

- CT is the preferred imaging choice for pregnant trauma patients, but make efforts to reduce radiation exposure while using an adequate radiation dose to generate a diagnostic test.
- In major trauma, the risks of ionizing radiation to the pregnant patient and fetus are small compared with the risk of missed or delayed maternal injury diagnosis.
- IV iodinated CT contrast material is a Food and Drug Administration (FDA) category B agent with no known adverse effects during pregnancy.
- Gadolinium, used with MRI, is a FDA category C agent with known teratogenic effects in animals, and it is contraindicated for pregnant patients.

Trauma is the leading cause of non-obstetric maternal mortality, and both major and minor trauma to the pregnant patient are associated with an increased risk of pregnancy loss.^{1,2} Delay in diagnosing injuries must be minimized. All centers should be familiar with issues regarding imaging during pregnancy.

Imaging Decisions

In major trauma, the pregnant patient is imaged with radiography, CT, and angiography as necessary. Imaging

begins with portable radiography of the chest and, when clinically indicated, the pelvis. FAST is performed in the trauma bay to identify free intraperitoneal fluid and pericardial fluid. Ultrasound also enables determination of gestational age, fetal heart rate, amniotic fluid volume, and placental position. Although free of ionizing radiation, ultrasound has limited utility in detecting maternal injuries, including active arterial bleeding.

Radiography, CT, and angiography produce ionizing radiation. In major trauma, the risks of radiation to the pregnant patient and fetus are small compared with the risk of missed or delayed diagnosis of maternal injury. MRI is safe in pregnancy at 1.5 T, although it is rarely performed in acute trauma. It removes the patient from emergency personnel, patient monitoring is difficult in this setting, and it is time intensive.

Radiographs

Shield the fetus for all but pelvic and lumbar spine films. Eliminate redundancy, for example, avoid pelvic radiographs if abdominopelvic CT will be performed.

Computed Tomography

CT is the best practice for the evaluation of trauma patients, and it remains the imaging choice for injured pregnant patients. Make efforts to eliminate unnecessary scans, reduce overlap of body sections, and avoid multiple passes where possible. Avoid the use of extreme low-dose protocols to assure that a diagnostic test is generated.



The treating physician determines the need for abdominopelvic CT in a pregnant patient to diagnose serious abdominal injury typically encountered in high-energy trauma, such as motor vehicle crashes. Serious abdominal injury is more common in pregnant patients than in patients who are not pregnant.² In a retrospective study conducted by two Level 1 trauma centers, 605 pregnant patients were evaluated, of which 7.9 percent (48) were evaluated with CT, and 50 percent of patients presented in the third trimester. Of patients evaluated by CT, 35 percent (N=17) had normal abdominopelvic CT scans. However, CT was valuable in identifying non-uterine injuries (31 percent, N=15), uterine and maternal injuries (27 percent, N=13), and abnormal placental enhancement (23 percent, N=11). Of the patients with abnormal placental enhancement 91 percent had fetal demise and one patient had uterine rupture.³

Diagnostic abdominopelvic CT is performed according to routine trauma center protocol with IV contrast delayed films as indicated (see General Section).

CT cystography is performed with a very-low-dose technique in at-risk patients to evaluate for bladder rupture when the following signs are present: gross hematuria and stranding, fluid around the bladder, microscopic hematuria in the setting of a pelvic fracture, or penetrating trauma. CT scans of the spine and bony pelvis are reconstructed from the original dataset. This is the same protocol used in trauma patients who are not pregnant.

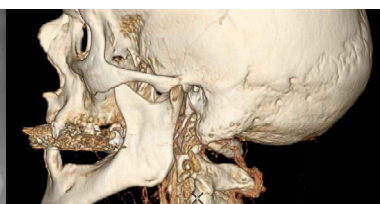
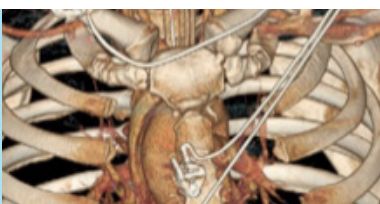
Contrast Materials

Intravenous iodinated CT contrast material is a FDA category B agent with no known adverse effects during pregnancy, and it is administered as necessary.⁴ Specifically, it does not alter neonatal thyroid function.⁵ Gadolinium, used with MRI, is a FDA category C agent with known teratogenic effects in animals, and it is contraindicated for pregnant patients.⁶

Angiography

Angiography is performed to diagnose and treat active bleeding in critically injured pregnant patients who do not meet the criteria for emergency surgery. Efforts are made to reduce the fluoroscopy radiation dose delivered to the gravid uterus. Where possible, radial artery access, rather than inguinal access, could be used to limit fluoroscopy time over the pelvis. If the patient is stable enough to first undergo CT, the interventional radiologist reviews the CT scan to determine the most likely site of bleeding to minimize the number of vessels that need to be injected. Strategies the interventional radiologist can use to reduce the fetal dose include the following:

- Minimize fluoroscopy time,
- Decrease the fluoroscopy frame rate,
- Minimize the number of spot films by using the last image hold feature when applicable,



- Tailor the DSA frame rate and total number of frames in a sequence to the anatomic area and blood flow rate being imaged,
- Use image magnification only as necessary, and
- Place a lead shield posterior to the gravid uterus if the site of bleeding is not the pelvis.

Although the initial assessment of the pregnant patient is performed with CT, follow up imaging in cases of abdominal or pelvic trauma may be performed with ultrasound or unenhanced MRI to reduce the cumulative dose from multiple CT examinations.

Radiation Risks and Pregnancy

Ionizing radiation has the potential to harm living tissue. The fetus is more sensitive to the harmful effects of ionizing radiation than children and adults. Fetal risks from ionizing radiation include small head size, developmental disability, organ malformations, cancer, and death.⁷ For these reasons physicians are reluctant to perform radiography and CT on pregnant patients.

Background radiation experienced by the fetus over the 9 months of gestation is estimated to be 1 mGy.⁸ Fetal radiation exposures of less than 1 milligray (mGy) are not significant, and parent counseling is not required.⁹ When the fetus is not in the field of view, the radiation dose is negligible. When the fetus is directly irradiated for pelvic radiography, the dose is approximately 1–3 mGy.⁹ The fetal dose from a typical CT of the abdomen and pelvis is 25 mGy.⁹ The fetal dose will

vary depending on scanning parameters. With modern CT scanners that use automated exposure control, the fetal dose may be reduced further, and it is reported to be as low as 13 mGy for CT of the abdomen and pelvis.¹⁰ The fetal dose from fluoroscopy over the gravid uterus for pelvic angiography is 20 – 100 mGy/min depending on maternal thickness and the number of vessels injected.

In 1977, the National Council of Radiation Protection and Measurements issued the following policy statement with regard to radiation and pregnancy: “The risk [of abnormality] is considered to be negligible at 50 mGy or less...”¹¹ Beginning in 2004 the American College of Obstetricians and Gynecologists issued statements that recommended women be informed that radiation exposure from a single diagnostic procedure does not result in harmful fetal effects.¹² Specifically, exposure to less than 5 rad [50 mGy] has not been associated with an increase in fetal anomalies or pregnancy loss.¹²

The risks of ionizing radiation to the fetus depend on the dose and the gestational age at exposure. In the first 2 weeks after conception, the main risk is spontaneous abortion. The effect is all or none, and it is only observed at doses greater than 50–100 mGy.¹³ Teratogenic effects, such as small head size, developmental disability, and organ malformations, are only observed at high doses (typically greater than 100 mGy) delivered between 2 and 15 weeks after conception. This is the period of organogenesis and rapid neuronal development and migration.¹³



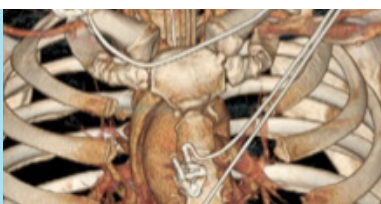In 2017, the American College of Obstetricians recommended that in the rare cases where exposures are above 60-310 mGy it is appropriate to counsel pregnant patients about associated concerns and individualized prenatal diagnostic imaging for structural anomalies and fetal growth restriction.¹⁴

The risk of childhood cancer from in utero exposure to ionizing radiation exists throughout pregnancy. Several reports place the background risk of childhood cancer mortality at 0.14 percent. An in utero exposure of 10 mGy increases this risk by 0.06 percent, which translates to 1 excess cancer death per 1,700.^{7,8}

Although not uniformly performed, dosimeter placement on the abdomen of pregnant patients can record radiation skin dose. If this is to be performed, the center must have an established protocol to estimate the fetal dose.¹⁵

References

1. Shah KH, Simons RK, Holbrook T, Fortlage D, Winchell RJ, Hoyt DB. Trauma in pregnancy: Maternal and fetal outcomes. *J Trauma*. 1998; 45: 83.
2. Pearlman MD, Tintinalli JE, Lorenz RP. Blunt trauma during pregnancy. *N Engl J Med* 1990; 323:1609–1613.
3. Lowdermilk C, Gavant ML, Qaisi W, West OC, Goldman SM. Screening helical CT for evaluation of blunt traumatic injury in the pregnant patient. *RadioGraphics*. 1999; 19: S243–S255; discussion, S243–S255.
4. Chen MM, Coakley FV, Kaimal A, Laros RK Jr. Guidelines for computed tomography and magnetic resonance imaging use during pregnancy and lactation. *Obstet Gynecol*. 2008; 112: 333–340.
5. Atwell TD, Lteif AN, Brown DL, McCann M, Townsend JE, Leroy AJ. Neonatal thyroid function after administration of IV iodinated contrast agent to 21 pregnant patients. *AJR*. 2008; 191: 268–271.
6. Theodorou DA, Velmahos GC, Souter I, et al. Fetal death after trauma in pregnancy. *Am Surg*. 2000; 66: 809–812.
7. Buschberg JT, Seibert JA, Leidholdt EM Jr, Boone JM. *The essential physics of medical imaging*, 2nd ed. Philadelphia, PA: Lippincott Williams & Wilkins; 2002.
8. Brent R, Mettler F, Wagner L, et al. Pregnancy and medical radiation: ICRP publication 84. International Commission on Radiological Protection. www.icrp.org/publication.asp?id=ICRP%20Publication%2084. Published 2000. Accessed April 18, 2018.
9. McCollough CH, Schueler BA, Atwell TD, et al. Radiation exposure and pregnancy: When should we be concerned? *RadioGraphics*. 2007; 27(4): 909– 917; discussion, 917–918.
10. Wieseler KM, Bhargava P, Kanal KM, Vaidya S, Stewart BK, Dighe MK. Imaging in pregnant patients: Examination appropriateness. *RadioGraphics*. 2010. 30(5): 1215–1229; discussion, 1230–1233.
11. National Council on Radiation Protection and Measurements. *Medical radiation exposure of pregnant and potentially pregnant women*. NCRP report no 54. Bethesda, MD: National Council on Radiation Protection and Measurements, 1977.
12. ACOG Committee on Obstetric Practice. ACOG Committee Opinion. Number 299, September 2004. Guidelines for diagnostic imaging during pregnancy. *Obstet Gynecol*. 2004; 104: 647–651.
13. Wagner LK. *Exposure of the pregnant patient to diagnostic radiation*. Madison, WI: Medical Physics Publishing, 1997.
14. ACOG Committee on Obstetric Practice. ACOG Committee Opinion. Number 723: Guidelines for diagnostic imaging during pregnancy and lactation. *Obstet Gynecol*. 2017; 130(4): e210–e216. doi: 10.1097/AOG.0000000000002355
15. Sadro C, Bernstein MP, Kanal KM. Imaging of Trauma: Part 2, Abdominal trauma and pregnancy – A radiologist’s guide to doing what is best for the mother and baby. *AJR* 2012; 199:1207-1219.



18. IMAGING IN GERIATRIC PATIENTS WITH LOW ENERGY MECHANISM INJURIES

Key Points

- The geriatric patient has a higher risk of injury following a low-impact injury mechanism (most often a ground-level fall) because of changes in physiology, balance, and flexibility.
- Have a very low threshold for requesting a head CT in geriatric patients for all head injuries, especially if they are taking anticoagulant medication.
- Imaging in geriatric trauma patients is more liberal because of greater risk for occult injuries and minimal risks related to radiation exposure.

The geriatric population (elderly persons, aged 65 and older) is projected to double in size, from 46 million in 2016 to more than 98 million by 2060. As a result, the geriatric share of the population is expected to grow from 15 percent to nearly 24 percent.² The geriatric population has higher rates of morbidity, mortality, readmissions, and functional decline when compared to younger adults due to the deadly combination of frailty, cognitive dysfunction, and injury.³ Their injuries tend to be underestimated by medical providers due to lack of awareness and age bias, which also contributes to adverse outcomes.⁴ Additionally, the geriatric

population is highly susceptible to trauma recidivism due to their physiologic and psychosocial vulnerability.⁵

The most common injury mechanism in the geriatric patient is a ground-level fall, accounting for 75 percent of trauma events, and 90 percent of those falls are from the standing position.⁶ Changes in physiology, especially age-related balance and flexibility deficits are responsible for the elderly adult's higher risk of injury following a low-impact mechanism. Osteoporosis and skeletal rigidity place them at higher risk for fracture. Additionally, loss of common reflexes places elderly adults at higher risk for hitting their face and head on the ground, potentially leading to severe TBI.

Because of age-related comorbidities like atrial fibrillation, coronary artery disease, and stroke, elderly adults are often prescribed daily anticoagulant and/or antithrombotic therapy. Patients taking these medications have higher rates of traumatic intracranial hemorrhage and subsequent mortality compared to elderly adults with similar injuries not on anticoagulant therapy (21.9 vs. 15.2 percent, respectively, $p=0.04$).^{7,8} A best practice is to obtain a coagulation profile in all geriatric trauma patients taking these medications and to obtain a head CT as soon as possible after admission.⁹

Imaging Considerations

In general, trauma surgeons are more liberal with imaging the geriatric patient because of minimal risks related to radiation exposure and greater risk for an unknown injury.⁹ Patients, aged 75



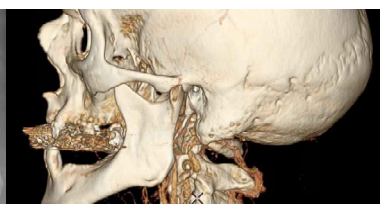
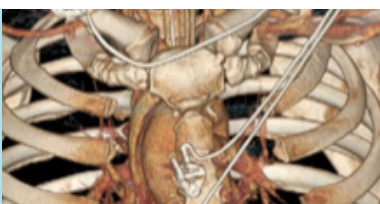
years and older, have the highest rates of hospitalization and death secondary to TBI, largely due to physiological vulnerabilities previously described.¹⁰ Diagnosis of intracranial hemorrhage in this population is difficult because they less often manifest neurological signs because of age-related brain atrophy. For this reason, the threshold to obtain a head CT in this population is very low. Perform a head CT on the patient with any type of head injury, especially if taking anticoagulant medication.¹¹ Monitor patients on anticoagulation or antiplatelet agents who have a normal head CT reading for a minimum of 4-8 hours to determine neurologic changes indicative of delayed hemorrhage. Additionally, have a low threshold for a follow up head CT to delineate a delayed bleed or the bleeding progression of a known closed head injury.

A common concern is inducing renal failure in a geriatric patient after administration of iodinated contrast agent, but studies reveal that it is largely unfounded. Age is not an independent risk factor for acute renal failure from iodinated contrast used for CT.¹² However, chronic renal failure is more common in older adults, and this condition is associated with a higher risk for contrast nephropathy. GFR can be used as a sensitive and specific test to determine a patient's capacity to tolerate iodinated contrast. A GFR greater than 60 mg/mL can be used as an approximate cutoff value for safe contrast administration.¹¹ In patients with a GFR less than 60 mg/mL, consider hydration with IV saline solution. However, in the case

of potential life-threatening injury, it is acceptable to go forward with contrast administration prior to GFR measurement. *Caution* -- do not use serum creatinine as the only indicator of adequate renal function in this population because age-related declines in skeletal muscle mass can result in lower baseline serum creatinine levels.^{11,12}

Spine fractures, including the C-spine, are also more common in these patients compared to younger adults. Half of geriatric C-spine fractures are clinically unstable.¹³ Additionally 21 percent of C-spine fractures in older adults are asymptomatic with no neck pain on presentation or examination.¹⁴ The NEXUS criteria are reported to be insufficient for the exclusion of C-spine injuries in geriatric patients.¹⁵ A best practice is liberal imaging for these patients regardless of injury mechanism or physical examination findings. Plain radiography is not sufficient for screening this population, rather C-spine CT is required for evaluation. C-spine CTA is recommended for screening when clinical suspicion of blunt cerebrovascular injury in the neck exists. Because of the increased incidence of spinal stenosis and degenerative disc disease, central cord syndrome or spinal cord injury without radiologic evidence is more common in the geriatric population, and MRI is recommended for its further evaluation.¹¹

Chest radiographs are a standard component of nearly all trauma evaluations. Chest radiographs are useful to identify life-threatening conditions such as pneumothorax



or hemothorax; however, they fail to identify up to 50 percent of rib fractures and have a low sensitivity for detection of aortic dissection.⁶ Maintain a low threshold to further evaluate any patient with clinically significant torso trauma using a chest CT.

The geriatric patient is more susceptible to pelvic fracture after an injury due to age-related bone density changes. Although the most common mechanism for pelvic ring fracture is a motor vehicle crash, it is important to keep in mind that pelvic fractures also commonly occur from low-energy falls in this population.¹⁶ The most common pelvic ring fracture type is a lateral compression fracture, which are five times more common than AP fractures.¹⁷ Geriatric patients are eight times more likely to suffer a major hemorrhage following a pelvic fracture (particularly a lateral compression fracture), and they have higher mortality rates.^{16,18,19}

A best practice is to screen every injured geriatric patient with an AP pelvic radiograph, and if any clinical suspicion for fracture exists, further evaluate the patient with a CT of the pelvis including IV contrast. The threshold for angioembolization (AE) in a geriatric patient with a pelvic blush is lower than in younger adults due to the higher rates of ongoing hemorrhage and adverse outcomes in the elderly. Rapidly initiate early IR consultation and AE for pelvic fracture patients with radiographic evidence of contrast extravasation, pelvic hematoma or hemodynamic compromise related to the pelvic fracture.^{6,18}

In the stable patient, MRI is more sensitive and specific than CT for patients with suspected occult hip fracture that have non-diagnostic radiographs.²⁰

Finally, consider the prognostic relevance of a fall in the older adult, especially one who is frail.^{21,22} Early involvement of palliative care expertise improves the quality of care delivered and symptom management, while decreasing the length of stay, cost, and the intensity of non-beneficial care at the end-of-life.^{23,24} Effective communication is especially important around prognosis, treatment options, and shared decision making in this vulnerable population. See the American College of Surgeons *Palliative Care Best Practice Guidelines*.

References

1. Mather M, Jacobsen LA, Pollard KM. *Aging in the United States. Population Bulletin*. 2015; 70(2). www.prb.org/pdf16/aging-us-population-bulletin.pdf. Accessed April 18, 2018
2. Passel JS, Cohn D. US population projections: 2005-2050. Pew Research Center. 2008. <http://www.pewhispanic.org/2008/02/11/ii-population-projections>. Accessed April 18, 2018.
3. Hildebrand F, Pape HC, Horst K, et al. Impact of age on the clinical outcomes of major trauma. *Eur J Trauma Emerg. S*. 2016; 42(3): 317-332.
4. Keller JM, Sciadini MF, Sinclair E, O'Toole RV. Geriatric trauma: Demographics, injuries, and mortality. *J Orthop Trauma*. 2012; 26(9): e161-165.
5. Joseph B, Orouji J, Kar T, Hassan A, et al. Redefining the association between old age and poor outcomes after trauma: The impact of frailty syndrome. *J Trauma Acute Care Surg*. 2017; 82(3): 575-581.
6. Callaway DW, Wolfe R. Geriatric trauma. *Emerg Med Clin North Am*. 2007; 25(3): 837-860.
7. Pieracci FM, Eachempati SR, Shou J, Hydo LJ, Barie PS. Use of long-term anticoagulation is associated with traumatic intracranial hemorrhage and subsequent mortality in elderly patients hospitalized after falls: Analysis of the New York State Administrative Database. *J Trauma Acute Care Surg*. 2007; 63(3): 519-524.



8. Hon HH, Elmously A, Stehly CD, et al. Inappropriate preinjury warfarin use in trauma patients: A call for a safety initiative. *J Postgrad Med.* 2016; 62(2): 73-79.
9. Calland JF, Ingraham AM, Martin N, et al. Evaluation and management of geriatric trauma: An Eastern Association for the Surgery of Trauma practice management guideline. *J Trauma Acute Care Surg.* 2012; 73(5): S345-350.
10. Thompson HJ, McCormick WC, Kagan SH. Traumatic brain injury in older adults: Epidemiology, outcomes, and future implications. *J Am Geriatr Soc.* 2006; 54(10): 1590-1595.
11. Sadro CT, Sandstrom CK, Verma N, Gunn ML. Geriatric Trauma: A radiologist's guide to imaging trauma patients aged 65 years and older. *RadiogGraphics.* 2015; 35(4): 1263-1285.
12. McGillicuddy, EA, Schuster KM, Kaplan LJ, et al. Contrast induced nephropathy in the elderly trauma patients. *J Trauma Acute Care Surg.* 2010; 68(2): 294-297.
13. Hu R, Mustard CA, Burns C. Epidemiology of incident spinal fracture in a complete population. *Spine.* 1996; 21(4): 492-499.
14. Healey CD, Spilman SK, King BD, Sherrill JE 2nd, Pelaez CA. Asymptomatic cervical spine fractures: Current guidelines can fail older patients. *J Trauma Acute Care Surg.* 2017 Jul; 83(1): 119-125. Doi: 10.1097/TA.0000000000001497.
15. Paykin G, O'Reilly G, Ackland HM, Mitra B. The NEXUS criteria are insufficient to exclude cervical spine fractures in older blunt trauma patients. *Injury.* 2017; 48(5): 1020-1024.
16. O'Brien D P, Luchette FA, Pereira SJ, et al. Pelvic fracture in the elderly is associated with increased mortality. *Surgery.* 2002; 132(4): 710-714; discussion 714-715.
17. Henry SM, Pollak AN, Jones AL, Boswell S, Scalea TM. Pelvic fracture in geriatric patients: A distinct clinical entity. *J Trauma Acute Care Surg.* 2002; 53(1): 15-20.
18. Velmahos GC, Toutouzias KG, Vassiliu P, et al. A prospective study on the safety and efficacy of angiographic embolization for pelvic and visceral injuries. *J Trauma Acute Care Surg* 2002; 53(2): 303-308; discussion 308.
19. Dechert TA, Duane TM, Frykberg BP, Aboutanos MB, Malhotra AK, Ivatury RR. Elderly patients with pelvic fracture: interventions and outcomes. *Am Surg.* 2009; 75(4): 291-295.
20. Haubro M, Stougaard C, Torfing T, Overgaard S. Sensitivity and specificity of CT- and MRI-scanning in evaluation of occult fracture of the proximal femur. *Injury.* 2015; 46(8): 1557-1561.
21. Maxwell CA, Mion LC, Mukherjee A, May A, Miller RS. Preinjury physical frailty and cognitive impairment among geriatric trauma patients determines post-injury functional recovery and survival. *J Trauma Acute Care Surg.* Feb 2016; 80: 195-203.
22. Moran CG, Wenn RT, Sikand M, Taylor AM. Early mortality after hip fracture: Is delay before surgery important? *J Bone Joint Surg.* 2005; 87(3): 483-489.
23. Mosenthal AC, Murphy PA, Barker LK, Lavery R, Retano A, Livingston DH. Changing the culture around end-of-life care in the trauma intensive care unit. *J Trauma Acute Care Surg.* 2008; 64(6): 1587-1593.
24. Toevs CC. Palliative medicine in the surgical intensive care unit and trauma. *Surg Clinics N Am.* 2011; 91(2): 325-331, viii.



19. IMAGING FOR INTENTIONAL INJURY IN CHILDREN

Key Points

- Radiologists need experience and sufficient expertise to interpret pediatric skeletal surveys performed to evaluate intentional injury and contribute to the investigation.
- When intentional injury is suspected a complete skeletal survey is recommended in all children 24-months of age and younger.
- When a high suspicion for intentional injury exists or is documented, perform a skeletal survey on siblings and household contacts who are 24-months of age and younger.
- When a suspicion of intentional injury exists in children 2-years and older who are able to verbalize areas of injury, focus initial imaging on the body regions of concern.
- CT of the head without contrast is indicated when children have neurologic signs or symptoms of injury, skull fractures, multiple fractures, spinal trauma, facial injury, or unexplained apnea.
- Have a low threshold for performing neuroimaging in children with suspected intentional injury, particularly in infants less than 12-months old.

More than 700,000 children were reported to be victims of maltreatment in the United States in 2014.¹ Intentional injury (physical abuse) was reported in 41 percent of these cases. Infants and toddlers were at greatest risk of being victimized and suffering severe or fatal injury.¹ Approximately 71 percent of all deaths occurred in children less than 3-years-old, and the death rate was highest for infants less than 1-year-old.¹

Initial Evaluation of Intentional Injury in Children

The initial clinical approach to the child with severe injuries follows the ATLS guidelines. When intentional injury is suspected, further evaluation is necessary to identify additional injuries that need treatment or to help distinguish them from unintentional injury. Physicians and social workers specializing in child abuse are often available at trauma centers that manage large numbers of children and can assist with this challenging work-up. To ensure that an appropriate work-up is performed, consider transferring a child to a facility with specialty physicians and social workers when these specialists are not available in your facility. A report to Child Protective Services is mandated when a reasonable suspicion of intentional injury exists. Transferring the patient for further work-up does not relieve the transferring physician of this reporting responsibility.



The American Academy of Pediatrics published a detailed report that guides the evaluation of suspected child intentional injury.² Highly suspicious history and physical exam findings include:

- Injury to a nonmobile infant, including bruises, oral injuries, or fractures,
- Injuries in unusual locations, such as over the torso, ears or neck,
- Patterned injuries,
- Injuries to multiple organ systems,
- Multiple injuries in different stages of healing, and
- Significant injuries that are unexplained or inconsistent with reported mechanism or patient's age or stage of development.

Skeletal Radiologic Survey

Imaging plays an important role in the identification of intentional physical injury. The ACR and Society for Pediatric Radiology (SPR) published practice parameters for the performance and interpretation of skeletal surveys in children in 2016.³ Radiologists need experience and sufficient expertise to interpret pediatric skeletal surveys to evaluate for intentional injury and contribute to the investigation. Technologists also need training and experience to perform skeletal survey radiographic examinations in infants and children. All radiology personnel must recognize the sensitive social environment created when patients

with possible intentional injuries are brought to the radiology suite for evaluation. The imaging work-up for suspected physical abuse is outlined in "ACR Appropriateness Criteria: Suspected Physical Abuse – Child," and it is based on the patient's age, evidence of neurological, thoracic, or abdominopelvic injury, as well as social factors.⁴

The skeletal survey is the primary imaging examination for detecting fractures. A complete survey includes frontal and lateral views of the skull and thorax, including the ribs and thoracic spine; lateral views of the C-spine and lumbosacral spine; oblique views of the ribs; and single frontal views of the long bones, hands, feet, chest, abdomen, and pelvis. Separate views of each arm, forearm, thigh, leg, hand and foot are acquired.⁴ A single "babygram" radiograph of the entire infant provides insufficient anatomic detail, and it has no role in the evaluation for suspected physical abuse.

Recommended technical equipment and parameters are outlined in the "ACR Practice Parameter for the Performance and Interpretation of Skeletal Surveys in Children."³ High-resolution mode on digital systems optimizes visualization of osseous structures. Select image display parameters to enhance bone detail.

A skeletal survey is recommended in all children 24-months-old and younger when intentional injury is suspected. When a high suspicion exists, a follow up skeletal survey after two weeks can identify previously occult fractures, clarify equivocal



findings, and provide information to help date fractures. Additionally perform a skeletal survey on siblings and household contacts of children with documented intentional injury who are 24-months-old and younger.

Among children 2 years and older who are able to verbalize areas of injury and in whom a suspicion of intentional injury exists, focus initial imaging on the body regions of concern. Consider a skeletal survey in this older group to document the presence or absence of injuries, or when unexplained head injuries, abdominal injuries, or suspicious fractures are identified.

Radiologic findings with greater specificity for intentional injury relate to the shaking mechanism of injury and include classic metaphyseal corner fractures and fractures of the ribs and spinous processes. Other suspicious radiologic findings include epiphyseal separation injuries, sternal and scapular fractures, and multiple fractures of varying age.

Head and Spine Imaging

CT of the head without contrast is indicated when children have neurologic signs or symptoms of injury, skull fractures, multiple fractures, spinal trauma, facial injury, or unexplained apnea.⁴ Sensitivity for detecting fractures and intracranial hemorrhage is increased by the use of multiplanar reformatted images and 3D volume rendering of the skull.^{5,6} Insufficient evidence supports universal screening with head CT in all cases of suspected intentional injury. However, many

cases of intracranial injury are reported in children with suspected intentional injury who have no clinical suspicion of intracranial pathology.^{7,8} The ACR advises clinicians to have a low threshold for performing neuroimaging in children with suspected intentional injury, particularly in infants less than 12-months-old.

MRI

MRI of the head is typically used in the nonemergent setting if a continued suspicion of head injury exists when a head CT is negative. MRI is also used to assess the extent of post-traumatic injury seen on CT. T1- and T2-weighted, T2 fluid attenuation inversion recovery (FLAIR), T2*, and diffusion-weighted sequences provide increased sensitivity for parenchymal ischemia, diffuse axonal injury, microhemorrhage, and small extra-axial hemorrhage.⁴ Contrast-enhanced sequences can help identify extra-axial collections and septations that suggest a chronic component. Unenhanced time-of-flight magnetic resonance venograms can assess the dural venous sinuses for patency when occlusive thrombosis is a concern.

C-spine injuries are common in the setting of intentional head trauma.⁹ The ACR recommends that clinicians consider performing an MRI of the C-spine at the time of brain MRI.⁴ An MRI of the thoracolumbar spine is not included in the routine imaging work-up, but when concern exists about a potential spinal cord injury, the MRI can help distinguish between unintentional and intentional injury by identifying subdural blood, which is a more common finding with intentional injury.¹⁰



Abdominal Imaging

Intentional injury is the second leading cause of abdominal injury in children, motor vehicle crashes are first. Always consider this mechanism of injury in the presence of other suspicious clinical examination findings and history.¹¹ Intraabdominal injuries account for up to 11 percent of injuries in children with intentional injury; however, they are the second highest cause of mortality, highlighting the importance of identifying these injuries.¹² Among children with intentional injuries, solid organ injuries are most common. Hollow-viscus injuries are also disproportionately represented among these children compared to those with unintentional injuries, with the duodenum and proximal jejunum being most frequently injured.^{13,14} Suspicion for intraabdominal injury is higher when abdominal pain, abdominal distention, abdominal bruising, or vomiting are found, but these signs and symptoms are not present in all children with an abdominal injury.

Screening tests to help identify patients with a potential occult abdominal injury needing CT imaging of the abdomen and pelvis include hepatic transaminase, amylase, and lipase levels, and urinalysis. Screening tests and threshold levels used may vary by facility depending on desired sensitivity and specificity. Hepatic transaminase levels greater than 80 IU/mL are reported to have a sensitivity and specificity of 83 percent for the detection of abdominal injury in the setting of intentional injury.^{15,16} The sensitivity

and specificity of amylase (62 and 78 percent, respectively) and lipase (61 and 79 percent, respectively) are lower.¹⁵

CT of the abdomen and pelvis with IV contrast is indicated in children with suspected abdominopelvic injury. Images are obtained in the portal-venous phase, with selected delayed images when warranted. Oral contrast is not recommended because it provides only minimal improved specificity, increases the risk of aspiration, and delays image acquisition.¹⁷ CT without contrast is not recommended.

Other Imaging

CT of the chest with IV contrast is recommended when clinical suspicion of intrathoracic vascular injury exists.⁴ CT of the chest without contrast has higher sensitivity for rib fractures than radiograph, but it is considered an adjunctive exam and routine use is not recommended.

Tc-99m whole-body bone scan is an adjunctive examination for the detection of fractures.⁴ It has utility when clinical suspicion is high, but the skeletal survey is negative or findings are equivocal or subtle. Venipuncture is required for radiotracer injection and sedation is often required because image acquisition requires a stationary patient for a longer interval compared to other modalities.

Ultrasound does not have a role in the imaging work-up of children with suspected intentional injury.



References

1. U.S. Department of Health & Human Services, Administration for Children and Families, Administration on Children, Youth and Families, Children's Bureau. Child maltreatment 2016. Available from <http://www.acf.hhs.gov/cb/resource/child-maltreatment-2016>. Accessed April 18, 2018.
2. Christian CW, Committee on Child Abuse and Neglect. The evaluation of suspected child physical abuse. *Pediatrics*. 2015 May 1; 135(5): e1337-54.
3. American College of Radiology. ACR-SPR practice parameter for the performance and interpretation of skeletal surveys in children. *Am Coll Radiol*. 2016. <https://www.acr.org/-/media/ACR/Files/Practice-Parameters/skeletal-survey.pdf?la=en> Accessed April 18, 2018.
4. Wootton-Gorges SL, Soares BP, Alazraki AL, et al. ACR Appropriateness Criteria® Suspected Physical Abuse—Child. *J Am Coll Radiol*. 2017 May 31; 14(5): S338-349.
5. Langford S, Panigrahy A, Narayanan S, et al. Multiplanar reconstructed CT images increased depiction of intracranial hemorrhages in pediatric head trauma. *Neuroradiology*. 2015 Dec 1; 57(12): 1263-1268.
6. Prabhu SP, Newton AW, Perez-Rossello JM, Kleinman PK. Three-dimensional skull models as a problem-solving tool in suspected child abuse. *Pediatr Radiol*. 2013 May 1; 43(5): 575-581.
7. Rubin DM, Christian CW, Bilaniuk LT, Zazyczny KA, Durbin DR. Occult head injury in high-risk abused children. *Pediatrics*. 2003 Jun 1; 111(6): 1382-1386.
8. Laskey AL, Holsti M, Runyan DK, Socolar RR. Occult head trauma in young suspected victims of physical abuse. *J Pediatr*. 2004 Jun 30; 144(6): 719-722.
9. Kadom N, Khademan Z, Vezina G, Shalaby-Rana E, Rice A, Hinds T. Usefulness of MRI detection of cervical spine and brain injuries in the evaluation of abusive head trauma. *Pediatr Radiol*. 2014 Jul 1; 44(7): 839-848.
10. Choudhary AK, Bradford RK, Dias MS, Moore GJ, Boal DK. Spinal subdural hemorrhage in abusive head trauma: A retrospective study. *Radiology*. 2012 Jan; 262(1): 216-223.
11. Trokel M, DiScala C, Terrin NC, Sege RD. Blunt abdominal injury in the young pediatric patient: Child abuse and patient outcomes. *Child Maltreat*. 2004 Feb; 9(1): 111-117.
12. Lane WG, Dubowitz H, Langenberg P, Dischinger P. Epidemiology of abusive abdominal trauma hospitalizations in United States children. *Child Abuse Negl*. 2012 Feb 29; 36(2): 142-148.
13. Hilmes MA, Hernanz-Schulman M, Greeley CS, Piercey LM, Yu C, Kan JH. CT identification of abdominal injuries in abused pre-school-age children. *Pediatr Radiol*. 2011 May 1; 41(5): 643-651.
14. Sheybani EF, Gonzalez-Araiza G, Kousari YM, Hulett RL, Menias CO. Pediatric nonaccidental abdominal trauma: What the radiologist should know. *RadioGraphics*. 2014 Jan; 34(1): 139-153.
15. Lindberg DM, Shapiro RA, Blood EA, Steiner RD, Berger RP, ExSTRA Investigators. Utility of hepatic transaminases in children with concern for abuse. *Pediatrics*. 2013 Feb 1; 131(2): 268-75.
16. Trout AT, Strouse PJ, Mohr BA, Khalatbari S, Myles JD. Abdominal and pelvic CT in cases of suspected abuse: Can clinical and laboratory findings guide its use? *Pediatr Radiol*. 2011 Jan 1; 41(1): 92-98.
17. Ellison AM, Quayle KS, Bonsu B, et al. Use of oral contrast for abdominal computed tomography in children with blunt torso trauma. *Ann Emerg Med*. 2015 Aug 31; 66(2): 107-114.



20. IMAGING AT RURAL TRAUMA CENTERS

Key Points

- Patients with injuries that exceed a facility's capabilities for treatment require only radiographs needed to identify potential life-threatening injuries that require intervention prior to transfer.
- Do not delay transfer to obtain additional radiologic images.
- All level I and II trauma centers must ensure capability to view and upload imaging studies from their referring facilities.
- A best practice is to have second-opinion radiology reads at the receiving trauma center, which are essential to identify clinically significant discrepancies that impact patient management.

Essential Imaging Needed

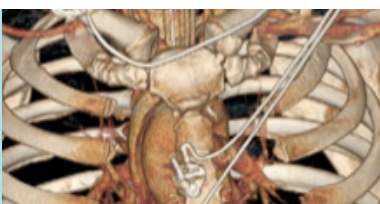
Rural trauma centers and facilities with limited subspecialty support often need to transfer patients to a higher level of care. Every facility with limited resources must know its own capabilities. ATLS guidelines emphasize early recognition of patients whose needs exceed the available resources and require transfer for further evaluation and definitive care. When diagnostic testing will not change the immediate plan of care, transfer must not be delayed.

Patients that obviously exceed a facility's capabilities require only those radiographs that will allow safe transfer. Chest and pelvic radiographs obtained as adjuncts to the primary survey identify potential life-threatening injuries that require intervention prior to transfer, such as a tube thoracostomy for pneumothorax or a pelvic binder for a pelvic fracture. Extremity films are recommended only if necessary to confirm reduction of a fracture or dislocation prior to transport.

Advanced imaging such as CT can prolong time to transfer, delay definitive care, and compromise outcomes.¹⁻³ However, imaging is often obtained to determine if patient transfer to a trauma center is necessary. In patients whose injuries exceed the capabilities of the facility but are not immediately obvious, follow ATLS guidelines and these best practice guidelines for the diagnostic work up of patients. Once a patient is found to have injuries that surpass the facility's capabilities, do not delay the transfer to obtain additional radiographic studies.

Transferring Images to the Trauma Center

Work out the best method for imaging study transfer between the referring facility and receiving trauma center in advance, such as through transfer agreements or statewide networks. The use of a cloud-based repository is an efficient method that allows receiving health care providers to review images prior to the patient's arrival. If images



must be sent on CD, ensure that the receiving trauma center has the ability to open and review the images. Despite the number of picture archiving and communication systems (PACS) being utilized across the country, most vendors provide software that enables the images to be viewed and uploaded on the receiving trauma centers' PACS. It is essential that all level I and II trauma centers perform an analysis of their referring facilities' imaging systems to ensure compatibility. A defined procedure in the trauma center's operation plan is important to ensure that images are uploaded on the receiving trauma center's PACS in a reliable and timely manner. The transferring facility must send radiology reports as soon as available, for inclusion in the patient's transferred electronic health record (EHR). These efforts are essential to avoid the need, expense, and risk of duplicate imaging.

The immediate availability of imaging studies on a cloud-based platform and/or a formal teleradiology arrangement is very useful in determining whether a patient requires transfer to a higher level of care. Early review of the referring facility's imaging studies helps determine the adequacy of the images and supports pre-arrival planning for additional imaging needed once the patient is received. Direct consultation with subspecialty surgeons and radiologists at the trauma center using an integrated PAC system or virtual private network (VPN) and cloud-based image sharing platforms can reduce the number of unnecessary transfers.^{4,5}

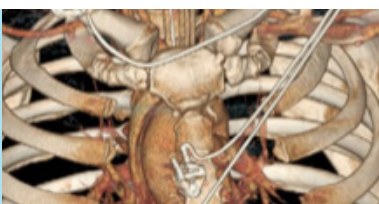
Delayed access to the study images or report, failure of electronic image transfers, suboptimal image quality, and inadequate technique with respect to phase of contrast, field of view, and reconstruction of multiplanar images can result in repeat CT at the trauma center.⁶⁻¹⁸ This adds radiation exposure to the patient, increases cost to the health care system, and may prolong time to treatment. The need for repeat imaging can be reduced by integrated PACS, VPN and cloud-based image sharing platforms, rapid upload of outside imaging studies to local PACS, and communication with referring facilities about preferred CT imaging protocols and parameters.¹⁸⁻²⁷ A best practice is to ensure that second-opinion radiology reads by receiving trauma center radiologists is performed. Clinically significant discrepancies that impact patient management are often identified.²⁷⁻³³

References

1. Gupta R, Greer SE, Martin ED. Inefficiencies in a rural trauma system: The burden of repeat imaging in interfacility transfers. *J Trauma Acute Care Surg*. 2010 Aug; 69(2): 253-255.
2. Härtl R, Gerber LM, Iacono L, Ni Q, Lyons K, Ghajar J. Direct transport within an organized state trauma system reduces mortality in patients with severe traumatic brain injury. *J Trauma Acute Care Surg*. 2006 Jun; 60(6): 1250-1256.
3. Mohan D, Barnato AE, Angus DC, Rosengart MR. Determinants of compliance with transfer guidelines for trauma patients: A retrospective analysis of CT scans acquired prior to transfer to a Level I trauma center. *Ann Surgery*. 2010 May; 251(5): 946-951.
4. Bible JE, Kadakia RJ, Kay HF, Zhang CE, Casimir GE, Devin CJ. How often are interfacility transfers of spine injury patients truly necessary? *The Spine Journal*. 2014 Dec; 14(12): 2877-2884.



5. Moya M, Valdez J, Yonas H, Alverson DC. The impact of a telehealth web-based solution on neurosurgery triage and consultation. *Telemedicine and e-Health*. 2010 Nov; 16(9): 945-949.
6. Liepert AE, Cochran A. CT utilization in transferred trauma patients. *J Surg Res*. 2011 Oct; 170(2): 309-313.
7. Young AJ, Meyers KS, Wolfe L, Duane TM. Repeat computed tomography for trauma patients undergoing transfer to a level I trauma center. *Am Surgeon*. 2012 Jun; 78(6): 675-678.
8. Jones AC, Woldemikael D, Fisher T, Hobbs GR, Prud'homme BJ, Bal GK. Repeated computed tomographic scans in transferred trauma patients: Indications, costs, and radiation exposure. *J Trauma Acute Care Surg*. 2012 Dec; 73(6): 1564-1569.
9. Emick DM, Carey TS, Charles AG, Shapiro ML. Repeat imaging in trauma transfers: A retrospective analysis of computed tomography scans repeated upon arrival to a level I trauma center. *J Trauma Acute Care Surg*. 2012 May; 72(5): 1255-1262.
10. Moore HB, Loomis SB, Destigter KK, et al. Airway, breathing, CT scanning: Duplicate computed tomography imaging after transfer to trauma center. *J Trauma Acute Care Surg*. 2013 Mar; 74(3): 813-817.
11. Hill AD, Catapano JS, Surina JB, Lu M, Althausen PL. Clinical and economic impact of duplicated radiographic studies in trauma patients transferred to a regional trauma center. *J Orthop Trauma*. 2015 Jul; 29(7): e214-8.
12. Hinzpeter R, Sprengel K, Wanner GA, Mildemberger P, Alkadhi H. Repeated CT scans in trauma transfers: An analysis of indications, radiation dose exposure, and costs. *Eur J Radiol*. 2017 Mar; 88: 135-140.
13. McNeeley MF, Gunn ML, Robinson JD. Transfer patient imaging: Current status, review of the literature, and the Harborview experience. *J Am Coll Radiol*. 2013 May; 10(5): 361-367.
14. Bible JE, Kadakia RJ, Kay HF, Zhang CE, Casimir GE, Devin CJ. Repeat spine imaging in transferred emergency department patients. *Spine*. 2014 Feb; 39(4): 291-296.
15. Berkseth TJ, Mathiason MA, Jafari ME, Cogbill TH, Patel NY. Consequences of increased use of computed tomography imaging for trauma patients in rural referring hospitals prior to transfer to a regional trauma centre. *Injury*. 2014 May; 45(5): 835-839.
16. Puckett Y, Bonacorsi L, Caley M, et al. Imaging before transfer to designated pediatric trauma centers exposes children to excess radiation. *J Trauma Acute Care Surg*. 2016 Aug; 81(2): 229-235.
17. Brinkman AS, Gill KG, Leys CM, Gosain A. Computed tomography-related radiation exposure in children transferred to a Level 1 pediatric trauma center. *J Trauma Acute Care Surg*. 2015 Jun; 78(6): 1134-1137.
18. Chwals WJ, Robinson AV, Sivit CJ, Alaedeen D, Fitzenrider E, Cizmar L. Computed tomography before transfer to a level I pediatric trauma center risks duplication with associated increased radiation exposure. *J Pediatr Surg*. 2008 Dec; 43(12): 2268-2272.
19. Sodickson A, Opraseuth J, Ledbetter S. Outside imaging in emergency department transfer patients: CD import reduces rates of subsequent imaging utilization. *Radiology*. 2011 Aug; 260(2): 408-413.
20. Lu MT, Tellis WM, Fidelman N, Qayyum A, Avrin DE. Reducing the rate of repeat imaging: Import of outside images to PACS. *Am J Roentgenol*. 2012 Mar; 198(3): 628-634.
21. Watson JJ, Moren A, Diggs B, et al. A statewide teleradiology system reduces radiation exposure and charges in transferred trauma patients. *Am J Surg*. 2016 May; 211(5): 908-912.
22. Mendelson DS, Bak PR, Menschik E, Siegel E. Image exchange: IHE and the evolution of image sharing. *Radiographics*. 2008 Nov; 28(7): 1817-1833.
23. Banerjee A, Zosa BM, Allen D, Wilczewski PA, Ferguson R, Claridge JA. Implementation of an image sharing system significantly reduced repeat computed tomographic imaging in a regional trauma system. *J Trauma Acute Care Surg*. 2016 Jan; 80(1): 51-56.
24. Psoter KJ, Roudsari BS, Vaughn M, Fine GC, Jarvik JG, Gunn ML. Effect of an image-sharing network on CT utilization for transferred trauma patients: A 5-year experience at a level I trauma center. *J Am Coll Radiol*. 2014 Jun 30; 11(6): 616-622.
25. Liepert AE, Bledsoe J, Stevens MH, Cochran A. Protecting trauma patients from duplicated computed tomography scans: The relevance of integrated care systems. *Am J Surg*. 2014 Oct; 208(4): 511-516.
26. Whiteman C, Kiefer C, D'Angelo J, Davidov D, Larrabee H, Davis S. The use of technology to reduce radiation exposure in trauma patients transferred to a level 1 trauma center. *W V Med J*. 2014 May; 110(3): 14-19.



27. Flanagan PT, Relyea-Chew A, Gross JA, Gunn ML. Using the internet for image transfer in a regional trauma network: Effect on CT repeat rate, cost, and radiation exposure. *J Am Coll Radiol*. 2012 Sep; 9(9): 648-656.
28. Zan E, Yousem DM, Carone M, Lewin JS. Second-opinion consultations in neuroradiology. *Radiology*. 2010 Mar; 255(1): 135-141.
29. Jeffers AB, Saghir A, Camacho M. Formal reporting of second-opinion CT interpretation: Experience and reimbursement in the emergency department setting. *Emerg Radiol*. 2012 Jun; 19(3): 187-193.
30. Lu MT, Tellis WM, Avrin DE. Providing formal reports for outside imaging and the rate of repeat imaging. *Am J Roentgenol*. 2014 Jul; 203(1): 107-110.
31. Khalilzadeh O, Rahimian M, Batchu V, Vadvala HV, Novelline RA, Choy G. Effectiveness of second-opinion radiology consultations to reassess the cervical spine CT scans: A study on trauma patients referred to a tertiary-care hospital. *Diagn Interv Radiol*. 2015 Sep; 21(5): 423-427.
32. Snow A, Milliren CE, Graham DA, et al. Quality of pediatric abdominal CT scans performed at a dedicated children's hospital and its referring institutions: A multifactorial evaluation. *Pediatr Radiol*. 2017 Apr 1; 47(4): 391-397.
33. Onwubiko C, Mooney DP. The value of official reinterpretation of trauma computed tomography scans from referring hospitals. *J Pediatr Surg*. 2016 Mar 31; 51(3): 486-489.



21. DEALING WITH INCIDENTAL FINDINGS

Key Points

- CT imaging results in a higher percentage of incidental findings than other imaging types, and the rate is higher in whole-body CT.
- A lower rate of significant incidental findings is reported in pediatric patients.
- Weigh the risks of radiation exposure, contrast administration, and psychological impact upon the patient against the benefits of further investigation of incidental findings of uncertain or doubtful clinical significance.
- Establish a communication system for follow up and management of all incidental findings as some represent neoplasms or other clinically significant health problems.

Incidental findings are defined as abnormalities or diagnoses *unrelated* to the clinical indication for which the imaging study was performed. Some providers refer to these incidental findings as “incidentalomas.” Incidental findings are common, and the incidence varies depending upon the body part imaged. Imaging that includes either the chest or abdomen is associated with a higher frequency of incidental findings. CT imaging results in a higher percentage of incidental findings than other imaging types.¹ Variable rates are reported depending upon body part

and type of findings included; however, the reported range is 30 to 56 percent in ED-requested studies that include the torso.²⁻⁶ Significant incidental findings are reported at a lower rate in pediatric patients; however, they are estimated to be found in 16 to 17 percent of pediatric trauma patients undergoing abdomen/pelvis CT scanning.^{7,8}

Given the large anatomic area covered in whole-body CT for trauma, the frequency of incidental findings is greater than with selected CT alone. The REACT-2 trial found the frequency of incidental findings in patients undergoing whole-body CT for trauma to be 43 percent, compared to a rate of 32.5 percent for selected CT scanning⁹ While many incidental findings were benign, 1 in 24 of the findings in the REACT-2 trial were found to be a neoplasm confirmed by pathology, and up to 42 percent of the incidental findings were considered capable of creating serious morbidity. Some incidental findings clearly have an appropriate impact on the patient’s future management, while others can result in unnecessary clinical work-up. Given the frequency of these findings, and the variable impact they have on patient care, it is recommended that each facility have a defined process for handling these findings when noted.

Management and Follow up

Follow up of incidental findings can be costly, and it is important to weigh the risks of radiation exposure, contrast administration, and psychological impact upon the patient against the benefits.⁹⁻¹¹ Incidental findings can also



increase length of stay.¹² Use evidence-based guidelines or criteria whenever feasible to avoid the costly work-up of findings that have doubtful clinical significance.¹³⁻¹⁴ When evidence-based guidelines are not utilized, studies report that the number of follow up recommendations increases.¹⁵⁻¹⁸ Review prior reports and images whenever feasible, as this can obviate the need for follow up of findings that are stable over time. See Table 9 for resources for selected incidental findings guidance.

Communication

When an incidental finding is determined to require follow up or further management, communicate this clearly to the referring clinician and subsequently to the patient. It is recommended that the radiology report conform to the *ACR Practice Parameter for Communication of Diagnostic Imaging Findings*.¹⁹ Record in the EHR that the incidental finding was communicated to the patient. Establish a procedure for communication of incidental findings added to any preliminary report and initial communication with the treating physician.

Communication procedure examples vary by facility, but include closed-loop communication, and in some cases a case manager or software solution.

Facilities are encouraged to use a communication system for all incidental findings. When a systematic approach to follow up is not utilized, reported rates of follow up are 9.8 to 29 percent.^{4,20,21} Munk *et al.* reported that fewer than half of the class 3 (most

significant) incidental findings found on imaging were documented in the discharge summary.⁵ Systems designed to ensure patient follow up improve both patient notification and follow up rates.^{20,22} Integrated software solutions designed to detect delays in diagnosis show some promise.²³⁻²⁴ Given the fact that some findings are subsequently found to represent neoplasms or other clinically significant entities, and published literature on poor follow up rates occur when this communication process is not specifically addressed, it is recommended that trauma centers establish a defined system for follow up and management of these findings.

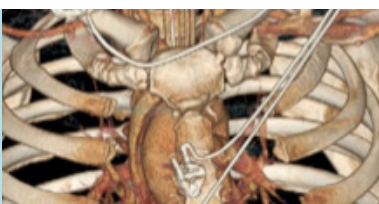
References

1. Lumbreras B, Donat L, Hernandez-Aguado I. Incidental findings in imaging diagnostic tests: A systematic review. *Br J Radiol.* 2010; 83: 276-289.
2. Barrett TW, Schierling M, Zhou C, et al. Prevalence of incidental findings in trauma patients detected by computed tomography imaging. *Am J Em Med.* 2009; 27(4): 428-435.
3. Devine AS, Jackson CS, Lyons L, Mason JD. Frequency of incidental findings on computed tomography of trauma patients. *W J Em Med.* 2010; 11(1): 24-27.
4. Thompson JR, Wojcik SM, Grant WD, Ko PY. Incidental findings on CT scans in the emergency department. *Emerg Med Int Print.* 2011: 624847, 2011.
5. Munk MD, Peitzman AB, Hostler DP, Wolfson AB. Frequency and follow-up of incidental findings on trauma computed tomography scans: Experience at a level one trauma center. *J Emerg Med.* 2010; 38(3): 346-50.
6. Fakler J, Ozkurtul O, Josten C. Retrospective analysis of incidental non-trauma associated findings in severely injured patients identified by whole-body spiral CT scans. *Patient Saf Surg.* 2014; 8: 36. <http://www.pssjournal.com/content/8/1/36>. Accessed April 18, 2018.



Table 9. References for Recommended Guidance for Incidental Findings Found with Imaging

Body Region and Type of Incidental Finding	Last Update	Reference
Pituitary findings on CT/MRI/PET	2018	Hoang JK et al. Management of incidental pituitary findings on CT, MRI, and 18F-Fluorodeoxyglucose PET: A white paper of the ACR Incidental Findings Committee. <i>J Am Coll Radiol.</i> 2018; 15: 966-972.
Thyroid on CT/MR	2015	Hoang, JK et al. Managing incidental thyroid nodules detected on imaging: White paper of the ACR Incidental Thyroid Findings Committee. <i>J Am Coll Radiol.</i> 2015; 12(2): 143-150.
Thyroid on ultrasound	2017	Tessler FN et al. ACR thyroid imaging, reporting and data system (TI-RADS): White paper of the ACR TI-RADS Committee. <i>J Am Coll Radiol.</i> 2017; 14(5): 587-595.
Lung nodules: Solid/subsolid (adult)	2017	MacMahon H, et al. Guidelines for management of incidental pulmonary nodules detected on CT Images: From the Fleischner Society 2017. <i>Radiol.</i> 2017; 284; 228-243.
Lung nodules (pediatric)	2015	No specific guideline. Refer to: Westra SJ et al. The incidental pulmonary nodule in a child. Part 2: Commentary and suggestions for clinical management, risk communication and prevention. <i>Pediatr Radiol.</i> 2015; 45: 634-639.
Mediastinal and cardiovascular findings on CT	2018	Menden RF, et al. Managing incidental findings on thoracic CT: Mediastinal and cardiovascular findings. A white paper of the ACR Incidental Findings Committee. <i>J Am Coll Radiol.</i> 2018; 15: 1087-1096.
Liver	2017	Gore, R et al. Management of incidental liver lesions on CT: A white paper of the ACR Incidental Findings Committee. <i>J Am Coll Radiol,</i> 2017; 14(11): 1429-1437.
Gallbladder/biliary	2013	Sebastian S et al. Managing incidental findings on abdominal and pelvic CT and MRI, Part 4: White paper of the ACR Incidental Findings Committee II on Gallbladder and Biliary Findings. <i>J Am Coll Radiol.</i> 2013; 10: 953-956.
Pancreatic cysts	2017	Megibow AJ et al. Management of incidental pancreatic cysts: A white paper of the ACR Incidental Findings Committee. <i>J Am Coll Radiol.</i> 2017 14(7): 911-923.
Spleen/abdominal nodes	2013	Heller MT, et al. Managing incidental findings on abdominal and pelvic CT and MRI, Part 3: White paper of the ACR Incidental Findings Committee II on Splenic and Nodal Findings. <i>J Am Coll Radiol.</i> 2013; 10: 833-839.
Kidney	2018	Herts BR et al. Management of the incidental renal mass on CT: A white paper of the ACR Incidental Findings Committee. <i>J Am Coll Radiol.</i> 2018; 15(2): 264-273. http://dx.doi.org/10.1016/j.jacr.2017.04.028
Adrenal	2017	Mayo-Smith WW et al. Management of incidental adrenal masses: A white paper of the ACR Incidental Findings Committee. <i>J Am Coll Radiol.</i> 2017; 14: 1038-1044.
Adnexal cyst on CT/MR	2013	Patel MD et al. Managing incidental findings on abdominal and pelvic CT and MRI, Part 1: White paper of the ACR Incidental Findings Committee II on Adnexal Findings. <i>J Am Coll Radiol.</i> 2013; 10: 675-681.
Adnexal cyst on ultrasound	2010	Levine D et al. Management of asymptomatic ovarian and other adnexal cysts imaged at US: Society of Radiologists in Ultrasound Consensus Conference Statement. <i>Radiology.</i> 2010; 256: 943-954.
Venous compression syndromes	2013	Khosa F et al. Managing incidental findings on abdominal and pelvic CT and MRI, Part 2: White paper of the ACR Incidental Findings Committee II on Vascular Findings. <i>J Am Coll Radiol.</i> 2013;10:789-794.



7. Daoud Y, Philip A, Altberg G, Leader H, Neuman J, Hahn B. Incidental findings on pediatric abdominal computed tomography at a pediatric trauma center. *J Emerg Med.* 2017; 53(5): 616-622.
8. Onwbiko C, Mooney DP. The prevalence of incidental findings on computed tomography of the abdomen/pelvis in pediatric trauma patients. *Eur J Trauma Emerg Surg.* 2017; 44(1): 15-18.
9. Treskes K, Bos SA, Sierink JC, et al, REACT-2 study group. High rates of clinically relevant incidental findings by total-body CT scanning in trauma patients; Results of the REACT-2 trial. *Emerg Radiol.* 2017; 27: 2451-2462.
10. Ding A, Eisenberg J, Pandharipande P. The economic burden of incidentally detected findings. *Radiol Clin N Am.* 2011; 49: 257-265.
11. Adams SJ, Babyn PS, Danilkewich A. Toward a comprehensive management strategy for incidental findings in imaging. *Can Fam Physician.* 2016; 62: 541-543.
12. Andrawes P, Picon AI, Shariff MA, et al. CT scan incidental findings in trauma patients: Does it impact hospital length of stay? *Trauma Surg Acute Care Open.* 2017; 2: 1-6.
13. McMahon H, Nadich DP, Jin NG, et al. Guidelines for management of incidental pulmonary nodules detected on CT images: From the Fleischner Society 2017. *Radiol.* 2017; 284: 228-243. doi.org/10.1148/radiol.2017161659
14. Hoang JK, Langer JE, Middleton WB, et al. Managing incidental thyroid nodules detected on imaging: White paper of the ACR Incidental Thyroid Findings Committee. *J Am Coll Radiol.* 2015; 12(2): 143-150.
15. Eisenberg RL. Ways to improve radiologists' adherence to Fleischner Society guidelines for management of pulmonary nodules. *J Am Coll Radiol.* 2013; 10: 439-441.
16. Masciocchi M, Wagner B, Lloyd B. Quality review: Fleischner criteria adherence by radiologists in a large community hospital. *J Am Coll Radiol.* 2012; 9: 336-339.
17. Clark TJ, Coats G. Adherence to ACR incidental finding guidelines. *J Am Coll Radiol.* 2016; 13: 1530-1533.
18. Lehnert BE, Sandstrom CK, Gross JA, Dighe M, Linnau KF. Variability in management recommendations for incidental thyroid nodules detected on CT of the cervical spine in the emergency department. *J Am Coll Radiol.* 2014; 11: 681-685.
19. ACR Practice Parameter for Communication of Diagnostic Imaging Findings. https://www.acr.org/~media/ACR/Documents/PGTS/guidelines/Comm_Diag_Imaging.pdf. Accessed 6/13/17.
20. Collins CE, Cherng N, McDade T, et al. Improving patient notification of solid abdominal viscera incidental findings with a standardized protocol. *J Trauma Manag Outcomes.* 2015; 9:1. DOI 10.1186/s13032-014-0022-x.
21. Sperry JS, Massaro MS, Collage RD, et al. Incidental radiographic findings following injury: Dedicated attention results in improved capture, documentation and management. *Surgery.* 2010; 148(4): 618-624.
22. Blagev DP, Lloyd JF, Conner K, et al. Follow-up of incidental pulmonary nodules and the radiology report. *J Am Coll Radiol.* 2014; 11(4): 378-383.
23. Murphy DR, Thomas E, Meyer AN, Singh H. Development and validation of electronic health record-based triggers to detect delays in follow-up of abnormal lung imaging findings. *Radiology.* 2015; 277(1): 81-87.
24. Shelver J, Wendt CH, McClure M, et al. Effect of an automated tracking registry on the rate of tracking failure in incidental pulmonary nodules. *J Am Coll Radiol.* 2017; 14(6): 773-777.



22. PERFORMANCE IMPROVEMENT AND IMPLEMENTATION

Key Points

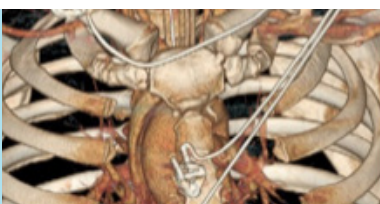
- Establish a collaborative partnership between the trauma program and radiology department to address trauma center criteria related to imaging the trauma patient and manage PI processes related to imaging.
- Establish processes to identify and manage delays in image order completion, timeliness of image interpretations, and quality of images that impact patient care or physician decision-making.
- Establish processes to monitor the use of pediatric-specific imaging guidelines and dosing for all pediatric imaging studies.
- Monitor the transfer of the patient's images and imaging interpretations to the definitive trauma care facility for timeliness and accuracy.

A collaborative partnership between leaders from a facility's trauma program and radiology department is essential to address the trauma center criteria specific to radiology defined by the most current edition of the *Resources for Optimal Care of the Injured Patient*.¹ This collaborative relationship facilitates the review and implementation of the *Imaging in Trauma Best Practice Guidelines* into the facility's trauma

management protocols and PI processes. The capabilities of each facility and its scope of services impact the overall implementation of these guidelines.

A major component of a trauma center's PI process is a focus on the appropriate use and timeliness of imaging. Key elements of the PI process include timeliness of the imaging completion after the physician's order, timeliness of imaging interpretations, and the quality of the imaging interpretations. Establish processes to identify and manage delays in either image acquisition or interpretation that impact patient care or physician decision-making. Integrate into the trauma center's PI process a method to monitor compliance with the imaging guidelines for specific injury patterns described in this document. Additionally include in the PI monitoring process any special imaging considerations (e.g. use of contrast) related to the patient's age, comorbidities, and specific disease processes, such as renal failure. A best practice for trauma centers that manage pediatric trauma patients is to have pediatric-specific imaging guidelines and dosing for all imaging studies, and to monitor this practice through the trauma PI process.

A procedure is required to transfer the patient's images between the transferring and receiving facilities when the injured patient is transferred for acute or definitive trauma care. This includes all pertinent imaging and the initial radiologist interpretations of the images. Receiving trauma centers need resources to expedite the re-review of the images



and measures to store the images. A recommended practice is to allow the receiving facility to have full control of the imaging quality and to receive the images electronically, as soon as the transfer is initiated. (See the Imaging at Rural Trauma Centers section.) Receiving trauma centers need to establish a PI process to monitor the timeliness of image transfer between the transferring and receiving trauma centers.

Reference

1. American College of Surgeons. *Resources for Optimal Care of the Injured Patient*. Chicago, IL; 2016. <https://www.facs.org/quality-programs/trauma/vrc> Accessed April 17, 2018.



Acronyms

2D—two-dimensional

3D—three-dimensional

AAST—American Association
for the Surgery of Trauma

ABI—ankle brachial index

ACR—American College of Radiology

ACS—American College of Surgeons

AE—angiobolization

AKI—acute kidney injury

AP—anteroposterior

ASA—American Society of Anesthesiologists

ATLS—Advanced Trauma Life Support

BAT—blunt abdominal trauma

BCVI—blunt cerebrovascular injury

BMI—body mass index

CCR—Canadian Cervical Rules

CD—compact disk

CDC—Centers for Disease Control
and Prevention

COT—Committee on Trauma

CT—computed tomography

CTA—computed tomography angiography

DSA—digital subtraction angiography

EAST—Eastern Association for the Surgery
of Trauma

ED—emergency department

eFAST—extended Focused Assessment
with Sonography in Trauma

EHR—electronic health record

FAST—Focused Assessment with
Sonography in Trauma

FDA—Food and Drug Administration

GCS—Glasgow Coma Scale or
Glasgow coma score

GFR—glomerular filtration rate

GU—genitourinary

ICH—intracranial hemorrhage

ICP—intracranial pressure

ICU—intensive care unit

INR—international normalized ratio

IR—interventional radiology

ISS—injury severity score

IV—intravenous

LOC—loss of consciousness

MDCT—4 channel or higher
multi-detector CT scan

mGy—milligray, a measure of radiation

MIP—maximum intensity projection

MRA—magnetic resonance angiography

MRCP—magnetic resonance
cholangiopancreatography

MRI—magnetic resonance imaging

MVC—motor vehicle crash

NEXUS—National Emergency
X-Radiography Utilization Study

OIS—organ injury scale

OR—operating room

PACS—picture archiving and
communication system

PECARN—Pediatric Emergency
Care Applied Research Network

PI—performance improvement

REACT-2—Randomized Study of Early
Assessment by CT Scanning Trial

REBOA—resuscitative endovascular
occlusion of the aorta

SCIWORA—formerly called spinal cord
injury without radiographic abnormality

SPR—Society for Pediatric Radiology

T—tesla, unit of magnet
strength measurement

TBI—traumatic brain injury

VPN—virtual private network

WBCT—whole-body CT



Appendix

The following terminology as defined was used in this best practice guideline:

Angioembolization—transcatheter embolization

Bariatric patient—morbidly obese patient

Catheter angiography—conventional angiography

Facility—non-trauma center medical institution, medical center, or hospital

Geriatric patient—an adult 65 years of age and older

Incidental findings—abnormalities or diagnoses that are unrelated to the clinical indication for which the imaging study was performed.

Multi-detector CT scan (MDCT)—4 channel or higher CT scan

Older adult—an adult 55 years of age and older

Radiographs—conventional films or x rays

Reconstructions—three-dimensional representation of CT data

Reformations—two-dimensional representations of CT data (for example, sagittal and coronal)

Trauma Center—refers specifically to Level I and Level II trauma centers

Traumatic brain injury—intracranial injury and injury to the head

Whole-body CT—CT of the head, cervical spine, chest, abdomen, and pelvis, also called a pan-CT



Expert Panel

Gail T. Tominaga, MD, FACS (Chair)
Chief, Trauma Section
Scripps Memorial Hospital La Jolla
La Jolla, California

Mark Bernstein, MD
Past-President, American Society of
Emergency Radiology
Clinical Associate Professor of Radiology
Trauma and Emergency Radiology
Department of Radiology
NYU Langone Health and Bellevue Trauma
New York, NY

RADIOLOGY

Michael R. Aquino, MD, MHSc
Pediatric Radiologist and Assistant Professor of
Medical Imaging
Hospital for Sick Children
Toronto, ON

Nicholas M. Beckmann, MD
Assistant Professor of Diagnostic and Interventional
Imaging
McGovern Medical School, The University of Texas
Health Science Center at Houston
Houston, TX

Sue E. Hanks, MD
Associate Professor of Clinical Radiology
Keck School of Medicine of USC
Los Angeles, CA

Susanna C. Spence, MD, CMQ
Associate Professor
Department of Diagnostic and
Interventional Imaging
McGovern Medical School at UTHealth
Houston, TX

O. Clark West, MD, FACR
Professor of Diagnostic and
Interventional Imaging
Vice-Chair for Clinical Operations and
Imaging Informatics
Chief of Emergency, Trauma,
and Musculoskeletal Imaging
McGovern Medical School, The University of Texas
Health Science Center at Houston
Houston, TX

PEDIATRIC TRAUMA

Randall S. Burd, MD, PhD, FACS
Chief, Division of Trauma and Burn Surgery
Children's National Medical Center
Washington, DC

Richard A. Falcone, Jr., MD, MPH, FACS
Associate Chief of Staff, Surgical Services
Trauma Medical Director
Professor of Surgery
Cincinnati Children's Hospital Medical Center
Cincinnati, OH

Barbara A. Gaines, MD, FACS
Professor, Surgery and Clinical and
Translational Science
University of Pittsburgh School of Medicine
Director, Trauma and Injury Prevention
UPMC Children's Hospital of Pittsburgh
Pittsburgh, PA

Aaron R. Jensen, MD, MEd, FACS, FAAP
Assistant Professor of Surgery
Keck School of Medicine of the University of Southern
California
Associate Trauma Medical Director
Children's Hospital Los Angeles
Los Angeles, CA

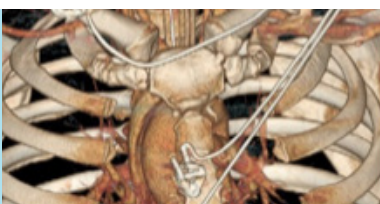
Kim Molik, MD, FACS
Pediatric Trauma Medical Director
Wesley Children's Hospital
Wichita, KS

ADULT TRAUMA

Christine S. Cocanour, MD, FACS, FCCM
Professor of Surgery
University of California Davis Health
Sacramento, CA

Chris Cribari, MD, FACS
Medical Director, Acute Care Surgery
UC Health Medical Group
Medical Center of the Rockies
Loveland, CO

Forrest B. Fernandez, MD, FACS
Section Chief Trauma, Acute Care Surgery,
and Surgical Critical Care
Reading Hospital
West Reading, PA



Lewis Jacobson, MD, FACS

*Chair, Department of Surgery
St. Vincent Indianapolis Hospital
Trauma Medical Director
Director, Surgical Critical Care
St. Vincent Indianapolis Level I Trauma Center
Indianapolis, IN*

David H. Livingston, MD, FACS

*Wesley J. Howe Professor of Surgery
Chief of Trauma and Surgical Critical Care
Rutgers-New Jersey Medical School
Newark, NJ*

Samuel P. Mandell, MD, MPH, FACS

*Assistant Professor
Harborview Medical Center,
University of Washington
Trauma, Critical Care, and Burn Surgery
Seattle, WA*

Anna N. Miller, MD, FACS

*Chief, Orthopaedic Trauma
Washington University in St. Louis
Barnes Jewish Hospital
St. Louis, MO*

Richard S. Miller, MD, FACS

*Professor of Surgery
Chief, Division of Trauma and Surgical Critical Care
Vanderbilt University Medical Center
Nashville, TN*

Nicole A. Stassen, MD, FACS, FCCM

*Professor of Surgery
University of Rochester Medical Center
Rochester, NY*

SCHOLARS

Melissa A. Hornor, MD, MS

*American College of Surgeons Clinical Scholar
in Residence
The Ohio State University Wexner Medical Center
Columbus, OH*

Jonathan P. Meizoso, MD, MSPH

*Resident in General Surgery
University of Miami/Jackson Memorial
Medical Center
Ryder Trauma Center
Miami, FL*

EDITOR

Jane W. Ball, RN, DrPH

*Pediatric Nursing and Trauma System Consultant
Gaithersburg, MD*

TRAUMA QUALITY PROGRAMS MEDICAL DIRECTOR

Avery B. Nathens MD, PhD, FRCS(C)

*Surgeon-in-Chief, Sunnybrook Health
Sciences Centre
Professor of Surgery, University of Toronto
De Souza Chair in Trauma Research
Toronto, ON*

ACS NURSE LIAISON

Jorie Klein, BSN, RN

*Director, Trauma Program, Rees-Jones
Trauma Center
Parkland Health and Hospital System
Dallas, TX*

STN NURSE PARTNERS

Anne Feeler, BSN, RN, CCRN

*Trauma Registry Manager
The Rees-Jones Trauma Center
Parkland Health & Hospital System
Dallas, TX*

**Jasmine Garces-King, DNP, RN, CCRN, TCRN,
ACNP-BC**

*Trauma Program Director
Division of Trauma, Acute Care Surgery, and Surgical
Critical Care
Orange Regional Medical Center
Middletown, NY*

Annemarie Glazer RN, BSN, MBA, TCRN

*Coordinator, Trauma Performance Improvement
and Research
North Shore University Hospital
Manhasset, NY*

Lisa Nichols MBA,BSN, RN, CCRN

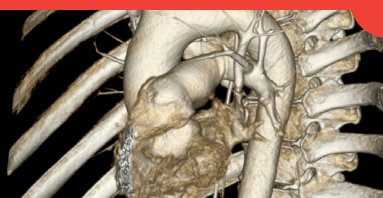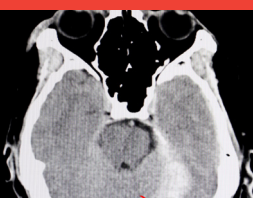*Trauma Program Manager
Dell Children's Medical Center
Austin, TX*

Sarah Parker, BSN, RN

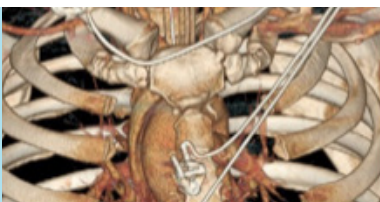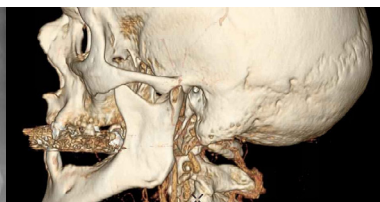
*Trauma Registry Manager
Grady Memorial Hospital
Atlanta, GA*

Stacey Staman, RN, MSN, CCRN-K, TCRN

*Trauma Program Coordinator, Pediatrics
Cooper University Hospital
Camden, NJ*



Notes





THE
COMMITTEE
ON **TRAUMA**



100+years

AMERICAN COLLEGE OF SURGEONS

*Inspiring Quality:
Highest Standards, Better Outcomes*